University of Rajshahi **Rajshahi-6205** **Bangladesh.**

RUCL Institutional Repository **http://rulrepository.ru.ac.bd**

Department of Veterinary and Animal Sciences MPhil Thesis

2014

Effect of Castration and Exogenous Testosterone Administration on Physio-biochemical Parameters and Male Accessory Sex Glands of Black Bengal Goat

Gofur, Md. Royhan

University of Rajshahi

http://rulrepository.ru.ac.bd/handle/123456789/198

Copyright to the University of Rajshahi. All rights reserved. Downloaded from RUCL Institutional Repository.

EFFECT OF CASTRATION AND EXOGENOUS TESTOSTERONE ADMINISTRATION ON PHYSIO-BIOCHEMICAL PARAMETERS AND MALE ACCESSORY SEX GLANDS OF BLACK BENGAL GOAT

A Thesis

By

MD. ROYHAN GOFUR
Roll No. 13614
Registration No. 10039
Session: 2013-2014

MASTER OF PHILOSOPHY (M. Phil.)

DEPARTMENT OF ANIMAL HUSBANDRY AND VETERINARY SCIENCE
FACULTY OF AGRICULTURE, UNIVERSITY OF RAJSHAHI
RAJSHAHI-6205, BANGLADESH

AUGUST 2014

EFFECT OF CASTRATION AND EXOGENOUS TESTOSTERONE ADMINISTRATION ON PHYSIO-BIOCHEMICAL PARAMETERS AND MALE ACCESSORY SEX GLANDS OF BLACK BENGAL GOAT

A Thesis

Submitted to
The Department of Animal Husbandry and Veterinary Science,
Faculty of Agriculture, University of Rajshahi, Rajshahi,
in partial fulfillment of the requirements
for the degree of

MASTER OF PHILOSOPHY (M. Phil.)

By

MD. ROYHAN GOFUR
Roll No. 13614
Registration No. 10039
Session: 2013-2014

DEPARTMENT OF ANIMAL HUSBANDRY AND VETERINARY SCIENCE
FACULTY OF AGRICULTURE, UNIVERSITY OF RAJSHAHI
RAJSHAHI-6205, BANGLADESH

AUGUST 2014

DEDICATED
TO MY
BELOVED PARENTS

Chapter 1

INTRODUCTION

Chapter 2

REVIEW OF LITERATURE

Chapter 3

MATERIALS AND METHODS

Chapter 4

RESULTS AND DISCUSSION

Chapter 5

SUMMARY AND CONCLUSIONS

REFERENCES

DECLARATION

I hereby declare that the thesis entitled **"Effect of Castration and Exogenous Testosterone Administration on Physio-biochemical Parameters and Male Accessory Sex Glands of Black Bengal Goat"** is the result of my own and original investigation to the Department of Animal Husbandry and Veterinary Science, Faculty of Agriculture, University of Rajshahi, Rajshahi-6205, Bangladesh under the supervision of **Dr. K. M. Mozaffor Hossain**, Associate Professor and Chairman, Department of Animal Husbandry and Veterinary Science, Faculty of Agriculture, University of Rajshahi, Rajshahi-6205, Bangladesh in fulfillment of the requirement for the degree of Master of Philosophy (M.Phil.)

I further declare that this research work has not been submitted in part or in full previously for any academic degree in this university or any university.

(Md. Royhan Gofur)
Candidate
Roll No. 13614
Registration No. 10039
Session: 2013-2014

July 2014
Rajshahi

CERTIFICATE

I am glad to certify the thesis entitled **"Effect of Castration and Exogenous Testosterone Administration on Physio-biochemical Parameters and Male Accessory Sex Glands of Black Bengal Goat"** submitted to the Department of Animal Husbandry and Veterinary Science, Faculty of Agriculture, University of Rajshahi, Rajshahi-6205, Bangladesh for the degree of Master of Philosophy (M. Phil.)

I hereby certify that

1) The candidate has fulfilled the residential requirements,
2) The research work embodied in the thesis has carried out by the candidate,
3) The data, as the best of my knowledge, are genuine and original and
4) No part of this research work has been submitted in substance for any academic degree.

Research Supervisor
Dr. K. M. Mozaffor Hossain
Associate Professor and Chairman
Department of Animal Husbandry and Veterinary Science
Faculty of Agriculture
University of Rajshahi
Rajshahi-6205, Bangladesh

ACKNOWLEDGEMENT

All praises are due to the Almighty Allah, Subhanuta'la, the Omnipotent, Omnipresent, Omniscient, and the Supreme authority of this universe, who enable the author to pursue higher education in Veterinary Science and to complete the research work and the thesis for the degree of Master of Philosophy (M. Phil.).

With great pleasure, the author would like to express his deepest sense of gratitude, sincere appreciation, profound regards and immense indebtedness to his research supervisor Dr. K. M. Mozaffor Hossain, Associate Professor and Chairman, Department of Animal Husbandry and Veterinary Science, Faculty of Agriculture, University of Rajshahi, Rajshahi-6205, Bangladesh for his research planning, scholastic guidance, sympathetic supervision, utmost desire, valuable suggestions, wise criticism, constructive and constant inspiration throughout the entire period of the research work and in preparation of this manuscript.

The author wishes to express the deepest sense of gratitude and heart-felt appreciation to all academic staffs of Department of Animal Husbandry and Veterinary Science, Faculty of Agriculture, University of Rajshahi, Rajshahi-6205, Bangladesh for their constant encouragement, valueable suggestions and cordial co-operation during whole study period.

The author wants to express special thanks and appreciations to University Grants Commission of Bangladesh for giving partly financial support. I would like to give thanks to Prof. Dr. Biswanath Sikder, Dept. of Genetic Engineering and Biotechnology, University of Rajshahi to allow me to work in the Prof. Joarder DNA & Chromosome Research Lab., Prof. Dr. Nurul Haque Mollah, Dept. of Statistics, University of Rajshahi to help me in Statistical Analysis, The Department of Pathology, Bangladesh Agricultural University and The Plasma Diagnostic Center, Laxmipur, Rajshahi to allow me to do part of my research work.

Thanks are extended to all of well wishers for their direct and indirect inspiration and help in completing this research work.

Last but no way to the least, the author wishes to express ever greateful and immensely indebted to his respected parents, beloved wife and relatives for their heartiest blessings, affectionate feelings, encouragement and all sorts of sacrifices for the author's higher education and successful completion of this humble research work.

The Author
July 2014

CONTENTS

CHAPTER	TITLE	PAGE
	ACKNOWLEDGEMENT	**v**
	CONTENTS	**vi**
	LIST OF TABLES	**vii**
	LIST OF FIGURES	**viii**
	LIST OF ABBREVIATION AND SYMBOLES	**ix-x**
	ABSTRACT	**xi**
1	**INTRODUCTION**	1-3
2	**REVIEW OF LITERATURE**	4-27
	2.1 Normal hemogram and serum biochemistry of goat	5
	2.2 Effect of castration and exogenous testosterone on blood parameters and serum biochemistry of goat	7
	2.3 Male accessory sex glands	16
	2.4 Effect of castration and exogenous testosterone on male accessory sex glands	24
3	**MATERIALS AND METHODS**	28-29
	3.1 Animals	28
	3.2 Collection of blood sample	28
	3.3 Hematological analysis	28
	3.4 Biochemical analysis	28
	3.5 Anatomical study	29
	3.6 Histological Study	29
	3.7 Measurement	29
	3.8 Photography	29
	3.9 Statistical analysis	
4	**RESULTS AND DISCUSSION**	30-48
	4.1 Effect of castration and exogenous testosterone on erythrocyte indices of goats	30
	4.2 Effect of castration and exogenous testosterone on leucocytes indices of goats	31
	4.3 Effect of castration and exogenous testosterone on serum biochemistry of goats	32
	4.4 Effect of castration and exogenous testosterone on male accessory sex glands	34
5	**SUMMARY AND CONCLUSIONS**	49
	REFERENCES	50-62

LIST OF TABLES

TABLE	TITLE	PAGE
Table-1	Normal values of red blood cell count, hemoglobin concentration, packed cells volume and erythrocyte indices of goat (according to different authors)	5
Table -2	Normal total leukocyte and differential leukocyte values of goat (according to different authors)	6
Table -3	Normal values of total serum cholesterol, triglyceride, high and low density lipoproteins of goat (according to different authors)	6
Table -4	Normal values of total serum proteins, albumin, globulin, glucose and enzymes of goat (according to different authors)	6
Table -5	Values of red blood cell count, hemoglobin concentration, packed cells volume and erythrocyte indices of castrated, control and testosterone treated goats	31
Table -6	Total leukocyte and differential leukocyte values of castrated, control and testosterone treated goats	32
Table -7	Values of total serum cholesterol, triglyceride, high and low density lipoproteins of castrated, control and testosterone treated goats	33
Table -8	Values of total serum proteins, albumin, globulin, glucose and enzymes of castrated, control and testosterone treated goats	34
Table -9	Length, width and weight of seminal vesicles in goats (mean ± SE)	35
Table-10	Length, width and weight of bulbourethral glands in goats (mean ± SE)	36
Table -11	Measurement of lamina muscularis and adventitia and glandular secretory unit of seminal vesicle in goats (mean ± SE)	42
Table -12	Measurement of lobule and glandular secretory unit of prostate gland in goats (mean ± SE)	46
Table -13	Capsular thickness of bulbourethral gland in goats (mean ± SE)	48

LIST OF FIGURES

FIGURE	TITLE	PAGE
Fig. 1	Schematic presentation of the urogenital organs of a bull	37
Fig. 2	Schematic presentation of the internal genital organs of bull	37
Fig. 3	Accessory sex glands of goat (treated with exogenous testosterone)	38
Fig. 4	Accessory sex glands of goat (castrated)	38
Fig. 5	Seminal vesicle of goat (treated with exogenous testosterone)	38
Fig. 6	Seminal vesicle of goat (castrated)	38
Fig. 7	Cross section of seminal vesicle of castrated goats (10X)	40
Fig. 8	Cross section of seminal vesicle of control goats (10X)	40
Fig. 9	Cross section of seminal vesicle of goats treated with exogenous testosterone (10X)	40
Fig. 10	Cross section of seminal vesicle of castrated goats (4X)	40
Fig. 11	Mucosa of seminal vesicle (10X)	41
Fig. 12	Mucosa of seminal vesicle (40X)	41
Fig. 13	Glandular secretory unit of seminal vesicle with secretion (10X)	41
Fig. 14	Glandular secretory unit of seminal vesicle of castrated goats (40X)	41
Fig. 15	Glandular secretory unit of seminal vesicle of control goats (40X)	41
Fig. 16	Glandular secretory unit of seminal vesicle of goats treated with exogenous testosterone (40X)	41
Fig. 17	Intralobular duct of seminal vesicle of goats (40X)	42
Fig. 18	Location of prostate gland (pars dessiminata) of castrated goats (4X)	44
Fig. 19	Location of prostate gland (pars dessiminata) of control goats (4X)	44
Fig. 20	Location of prostate gland (pars dessiminata) of goats treated with exogenous testosterone (4X)	44
Fig. 21	Cross section of prostate gland (pars dessiminata) of castrated goats (10X)	44
Fig. 22	Cross section of prostate gland (pars dessiminata) of control goats (10X)	45
Fig. 23	Cross section of prostate gland (pars dessiminata) of goats treated with exogenous testosterone (10X)	45
Fig. 24	Secretory unit of prostate glands (pars dessiminata) of goats (100X)	45
Fig. 25	Cross section of bulbo-urethral gland of castrated goats (10X)	47
Fig. 26	Cross section of bulbo-urethral gland of control goats (10X)	47
Fig. 27	Cross section of bulbo-urethral gland of goats treated with exogenous testosterone (10X)	47
Fig. 28	Capsule and trabeculae of bulbo-urethral gland of goats (10X)	47
Fig. 29	Secretory unit of bulbo-urethral glands of goats (40X)	47
Fig. 30	Intraglandular duct of bulbo-urethral glands of goats (10X)	47

ABBREVIATIONS AND SYMBOLS

&	=	And
Cm	=	Centimeter
DNA	=	Deoxyribonucleic Acid
RNA	=	Ribonucleic Acid
et al.	=	and Others
Fig.	=	Figure
g/gm	=	Gram
Mg	=	Miligram
i.e.	=	That is
Kg	=	Kilogram
SE	=	Standard Error
Vs	=	Versus
M	=	Micron/ Micrometer
Ml	=	Microliter
Dl	=	Deciliter
Fl	=	Femtoliter
Pg	=	Picogram
Wt	=	Weight
BW	=	Body Weight
Hg	=	Hemoglobin
PCV	=	Packed Cell Volume
MCV	=	Mean corpuscular volume
MCH	=	Mean corpuscular hemoglobin
MCHC	=	Mean corpuscular hemoglobin concentration
TC	=	Total cholesterol
TG	=	Triglycerides
Hct	=	Hematocrit
RBC	=	Red blood corpuscles
WBC	=	White blood corpuscles
ALP	=	Alkaline phosphatase
AST	=	Aspartate transaminase
TP	=	Total Protein
SGOT	=	Serum glutamic oxaloacetic transaminase
SGPT	=	Serum glutamic-pyruvic transaminase

IM	=	Intramuscular
SC	=	Subcutaneous
EPO	=	Erythropoietin
T/ TT	=	Testosterone
FT	=	Fetal testosterone
TE	=	Testosterone enanthate
TP	=	Testosterone propionate
TU	=	Testosterone undeconate
E	=	Ethinylestradiol
HDL	=	High density lipoprotein
HDL-C	=	High density lipoprotein- Cholesterol
LDL	=	Low density lipoprotein
LDL-C	=	Low density lipoprotein- Cholesterol
VLDL	=	Very low density lipoprotein
WAD	=	West African Dwarf
LHRHA	=	Long-acting gonadotrophin releasing hormone analog
PSA	=	Prostate-specific antigen
FBN	=	Fibrinogen
hMSC	=	Human Mesenchymal stem cell
DHT	=	Dihydrotestesterone
CVD	=	Cardiovascular disease
SHBG	=	Sex hormone binding globulin
PAS	=	Periodic Acid-Schiff
AB	=	Alcian Blue
BG	=	Bulbourethral Gland
VG	=	Vesicular Gland
GDP	=	Gross Domestic Product
BBS	=	Bangladesh Bureau of Statistics
EDTA	=	Ethylenediaminetetraacetic acid
DPX	=	Distrene, Plasticiser, Xylene
ANOVA	=	Analysis of variance
Viz	=	Namely

EFFECT OF CASTRATION AND EXOGENOUS TESTOSTERONE ADMINISTRATION ON PHYSIO-BIOCHEMICAL PARAMETERS AND MALE ACCESSORY SEX GLANDS OF BLACK BENGAL GOAT

ABSTRACT

Gofur MR (2014). Effect of castration and exogenous testosterone administration on physio-biochemical parameters and male accessory sex glands of Black Bengal goat

Testosterone, the principal androgen, exerts both androgenic effects involving growth stimulation and functional maintenance of the male reproductive tract and anabolic effects involving growth stimulation of non-reproductive organs and also affects the hemogram of animals. The study was conducted to uncover the effect of castration and administration of exogenous testosterone on physio-biochemical parameters and male accessory sex glands of Black Bengal goat. Fifteen male goats (4 months old) were divided into three groups; Group-A: Goats (castrated), Group-B: Control group and Group-C: Goats with excess testosterone (exogenous IM administration of testosterone enanthate, TE @ 125 mg/goat weekly for a period of 2 months). Castration caused a significant decrease in red blood corpuscles (RBC), packed cell volume (PCV) and percentage of lymphocytes accompanied with significantly increased mean corpuscular volume (MCV), mean corpuscular hemoglobin (MCH), and percentage of neutrophils compared with control group. Treatment with TE caused a significant increase in RBC, PCV and a significant decrease in total number of leucocytes and percentage of neutrophils. The study showed a significant increase in the levels of total cholesterol (TC), triglycerides (TG) and low density lipoprotein (LDL) in castrated group compared with control value. Administration of TE significantly decreased in the levels of TG and LDL compared with control group. A significant decline was observed in total protein, albumin and glucose level in castrated goats. The study showed no significant differences between groups in mean corpuscular hemoglobin concentration (MCHC), high density lipoproteins (HDL), globulin and serum enzyme (SGOT & SGPT) level. There was a significant difference on the length, width and weight of seminal vesicles and bulbourethral glands among three groups of goats indicated that the developmental dependence of the reproductive accessory glands on testosterone. The secretory units of the vesicular glands of all groups were lined by pseudostratified columnar epithelium consisted of tall columnar type cells and short basal type cells. The vesicular secretion was stored in the lumen of secretory units. It was also found the myoepithelial cells around the secretory cells of glandular end pieces of seminal vesicle in all groups of goats that helped in the excretion of vesicular secretion. The thickness of lamina muscularis and adventitia of seminal vesicle decreased gradually and the length and width of glandular secretory unit in propria-submucosa of seminal vesicle increased gradually along with the increment of the level of testosterone. All goats of present study had only pars disseminata (internal portion) and located in the propria-submucosa of the dorsal wall of pelvic urethra. The parenchyma comprised of secretory end pieces and ducts. The secretory units and intraglandular ducts of the prostate gland were lined by simple cuboidal to columnar epithelium with occasional basal cells. The length and width of lobes of prostate glands were significantly decreased in castrated goats and significantly increased in testosterone treated goats. The length and width of secretory units of prostate glands were reduced markedly in castrated goats. The bulbourethral glands (BG) were surrounded by the bulbocavernous muscle and the secretory units were lined with a tall simple columnar epithelium and occasional basal cells. Most of the columnar cells were of the mucous type, with the nuclei basally placed and the cytoplasm contained the secretion granules in all groups. The thickness of capsule of BG of TE treated goats reduced significantly. It can be concluded that castration and exogenous administration of testosterone in goats affect significantly in certain blood constituents and lipid & protein profile. The present findings also provide clear evidence of influence of castration and exogenous testosterone administration on the development of male accessory sex glands in the postnatal life of Black Bengal goat.

Key words: castration, exogenous testosterone, hematology, serum biochemistry, accessory sex glands, Black Bengal goat

INTRODUCTION

Despite the social and economic values of goats as source of meat, milk and hides, with a great production potential, research on goats, especially on Black Bengal goats (*Capra hircus*) usually neglected in our country.

Black Bengal goat is an important animal resource that plays an immense role in the development of livestock sector, to alleviate the poverty from our country and takes a great part in the increment of GDP of Bangladesh. Livestock is an integral component of agricultural economy of Bangladesh. The current contribution of livestock sub-sector to the GDP is 2.95 percent, which is estimated about 17.32 percent GDP to agriculture (BBS, 2012) in which share of goat is enormous. Ministry of Fisheries and Livestock was undertaken a national program namely "Poverty reduction through improvement of goat and increasing its production". The goats' revaluation depends on various factors, including the great prevalence of diseases, poor management practices and extensive production systems (Babeker and Elmansoury, 2013). So it is necessary to take initiatives for large scale research on Black Bengal goats for the development of livestock sector and ultimately the agricultural economy of our country.

Testis is the principle organ of male reproduction (reproductive system) and responsible for production of male germ cell (spermatozoa) and androgens, mainly testosterone. The accessory genital glands of males in goat are located along the pelvic portion of the urethra, with their ducts which open and empty their secretion into the urethral passage. They are the ampullae, the vesicular glands (seminal vesicle), the prostate gland and the bulbourethral glands (Getty, 1975; Bacha and Wood, 1990; Ghosh, 1995; Dyce *et al.,* 2002; Archana *et al.,* 2009). Accessory glands secrete additional fluids, which when combined with the sperm and other secretions from the epididymis, form the semen. They contribute greatly to the fluid volume of semen. Their secretions are solution of buffers, nutrients and other substances needed to assure optium motility and fertility of spermatozoa (Hafez, 1974; McDonald, 1980; Bone, 1988) and acts as a buffer against excess acidity of the female genital tract (Cunningham, 2002; Frandson and Spurgeon,

1992). These secretions are added quickly and forcibly during the mating to propel sperm into the urethra (Frandson and Spurgeon, 1992).

Testosterone, the principal androgen, secreted by Leydig cells, exerts both androgenic effects involving growth stimulation and functional maintenance of the male reproductive tract and anabolic effects involving growth stimulation of nonreproductive organs, such as muscle, kidney and liver (Barbara *et al.,* 2006) and also affects the hemogram of animals (Aydilek and Aksakal, 2005). Testosterone (androgen) is involved in regulating the oxidative phase of carbohydrate metabolism (Barbara *et al.,* 2006) and also improves the lipid metabolism (Gupta *et al*., 2008).

Blood is an important and reliable medium for assessing the health status of individual animals (Oduye, 1976). Haemato-biochemical parameters are good indicators of the physiological status of animals (Khan and Zafar, 2005). The hematological tests served as information base for animal health assistance.

Castration has been shown to elicit physiological stress, pain-associated behaviour, suppression of immune function, and a reduction in performance (Molony *et al.,* 1995) to varying degrees. Castration causes suppression cell-mediated immunity (Fisher *et al.,* 2001). Several non-genetic factors including castration affecting haematological parameters of farm animals have been observed (Carlson, 1996; Svoboda *et al.,* 2005). Deficiency of testosterone can cause a wide range of signs and symptoms including decreased sex drive, increased risk of osteoporosis, body hair loss, reduced muscle mass and strength, weaker erections of penis, lower body weight, lowered sperm count and excess testosterone increase the risk of prostate cancer.

A few scientists (Kumar and Majumder, 1995; Tyagi *et al.,* 1999; Hassan, 2010; Zha *et al.,* 2013 etc.) observed the effect of castration and testosterone in rats, rabbits and monkeys but there was no study conducted on the effect of testosterone (either excess or deficiency) on the physio-biochemical parameters and on the texture (gross and histological structure) of male accessory sex glands of domestic animals especially on the Black Bengal goat. So, this research was designed to observe the changes on physio-biochemical parameters and the gross and histological changes of male accessory sex

glands of male Black Bengal goat due to the deficiency (castration) and excess (exogenous administration) of testosterone (testosterone enanthate) which is necessary to know for a Professional to evaluate the status of breeding soundness of a breeding buck.

Significance: Goat is an important species of animals in respect of our country (Goat = Poor women's cow). Reproduction is an important phenomenon in livestock sector and soundness of testis (male gonad) and male accessory sex glands are essential for effective male reproduction. So, the result of this research may help to understand the influence of testosterone (deficit or excess) on the physio-biochemical parameters (blood, lipid & protein parameters) and on the development and function of accessory sex glands in the buck. This study may also help to understand health status and normal reproduction process, to increase the production in livestock sector. Such knowledge is essential for a Professional to evaluate the status of breeding soundness of a breeding buck.

Objectives: The present study was designed with the following objectives:

- To examine the effect of castration and exogenous testosterone administration on hematological and biochemical parameters of goats (control and with deficient and excess testosterone).
- To observe the effect of castration and exogenous testosterone administration on different gross anatomical parameters (length, width and weight) and histomorphological structure of seminal vesicles, prostate gland and bulbourethral glands of goats (control and with deficient and excess testosterone).

REVIEW OF LITERATURE

Goats (*Capra hircus*) are multipurpose animals that produce milk, skin, meat and hair. They are able to thrive as meat producers under conditions where other animals may find difficult (Oyeyemi *et al*., 2001). Goat production in Bangladesh makes a major contribution to the agrarian economy. Serum biochemistry and hematological analysis have been found to be important and reliable means for assessing an animal's health status and might give an indication of the degree of damage to host tissue as well as severity of infection (Otesile *et al.*, 1991). Haematological values could serve as baseline information for comparison in conditions of nutrient deficiency, physiology and health status of farm animals (Daramola *et al.,* 2005). Testosterone plays a crucial role in the proper development of male reproductive tissues (Winters, 1999) and affect the hemogram of animals.

Blood act as a pathological reflector of the status of the exposed animals to toxicants and other conditions. The examination of blood provides the opportunity to clinically investigate the presence of metabolites and other constituents in the body of animals and it plays a vital role in the physiological, nutritional and pathological status of an animal (Etim *et al.,* 2014; Olafedehan *et al.,* 2010).

Haematology refers to the study of the numbers and morphology of the cellular elements of the blood and the use of these results in the diagnosis and monitoring of disease (Merck Manual, 2012). Haematological studies are of ecological and physiological interest in helping to understand the relationship of blood characteristics to the environment (Ovuru and Ekweozor, 2004) and so, could be useful in the selection of animals that are genetically resistant to certain diseases and environmental conditions (Mmereole, 2008; Isaac *et al.,* 2013). Haematological parameters are good indicators of the physiological status of animals (Khan and Zafar, 2005). As reported by Isaac *et al.* (2013), animals with good blood composition are likely to show good performance. Laboratory tests on the blood are vital tools that help detect any deviation from normal in the animal or human body (Ogunbajo *et al.,* 2009). Blood constituents change in relation to the physiological conditions of health (Togun *et al.,* 2007). These changes are of value in assessing response of animals to various physiological situations (Khan and Zafar, 2005). Determination of

the haematological and biochemical parameters of animals helps veterinarians to confirm clinical diagnoses, determine stresses due to environmental, nutritional and/or pathological factors, estimate the severity of cases, administer appropriate treatment, and evaluate outcomes (Roubies *et al.,* 2006; Afolabi *et al*., 2010).

The genetic and non-genetic factors affecting haematological parameters of farm animals have been observed (Svoboda *et al.,* 2005; Xie *et al.*, 2013). Several factors including physiological (Alodan and Mashaly, 1999), environmental condition (Vecerek *et al.,* 2002), age (Seiser *et al.,* 2000), administration of drugs (Khan *et al.,* 1994) and continuous supplementation of vitamin (Tras *et al.,* 2000) affect the blood profile of healthy animal. Carlson (1996) and Johnston and Morris (1996) reported that besides physiological and environmental factors that might affect blood values such as age of the animal, factors such as oestrus cycle, pregnancy and parturition, genetics, method of breeding, breeds of animal, housing, feeding, fasting, extreme climatic conditions, stress, exercises, transport, castration and diseases have been identified.

2.1 Normal hemogram and serum biochemistry of goat

Haematological parameters and its knowledge can be used to assess the health as well as the physiological status of farm animals under consideration (Etim *et al.,* 2014). Different authors enumerate different normal hematological and serum values of goat that are summarized in table 1-4.

Table 1: Normal values of red blood cell count, hemoglobin concentration, packed cells volume and erythrocyte indices of goat (according to different authors)

Authors and Parameters	Red blood corpuscles 10^6×/µl	Hemoglobin (g/dl)	Packed cell Volume %	MCV (fl)	MCH (pg)	MCHC (g/dl)
Harvey (1962)		10.6				
Swenson (1977)	13-14			16	8	32
Sastry (1983)	8-18	8-14	9-38	15-30	10-12	35-42
Coles (1986)	8-17	8-14	20-38	16-25	5-8	28-34
Plumb (1999)	8.0 -18.0	8.0-12.0	22 – 38	16-25	5.2 - 8.0	30 – 36
Feldman *et al.* (2000)	8-18	8-12	22-38	16-25	5.2-8.0	30-36
Daramola *et al.* (2005)	11.5 ± 0.4	9.8± 0.3	29.4 ± 0.8			33.1±0.1
Olaifa & Opara(2011)	7-21	8-16	19-40	15-39	7.27±0.30	32-40

Table 2: Normal total leukocyte and differential leukocyte values of goat (according to different authors)

Authors and Parameters	White blood Cells 10^3×/µl	Neutrophil %	Eosinophil %	Basophil %	Lymphocyte %	Monocyte %
Breazile *et al.* (1971)	4-13	10-50	0-10	-	40-75	0-6
Reece (1991)	8-12	35-40	2-5	<1	50-55	5
Sastry (1983)	4-13	10-59	0-10	0-2	40-75	0-6
Feldman *et al.* (2000)	4-13	30-48	1-8	0-1	50-70	0-4
Coles (1986)	4-13	30-48	3-8	0-2	50-70	1-4
Swenson (1977)	8-12	35-40	2-5	<1	50-55	5
Daramola *et al.* (2005)	13.5 + 0.8	17 – 52	1 – 7	-	47 – 82	0-1
Plumb (1999)	4.0 -13.0	30 – 48	1 – 8	0-1	50 -70	0 – 4

Table 3: Normal values of total serum cholesterol, triglyceride, high and low density lipoproteins of goat (according to different authors)

Authors and Parameters	Cholesterol Mg/dl	Triglyceride mg/dl	High density Lipoproteins (HDL) mg/dl	Low density Lipoproteins (LDL) mg/dl
Swenson (1977)	55-200			
Sastry (1983)	55-200			
Plumb (1999)	64.6 - 136.4			
Solaiman *et al.* (2006)	65.6	45.6		
Elitok (2012)		45.62±2.38	55.66±3.34	24.13±2.46
Monfared (2013)	47.25 ± 2.9	46.6 ± 1.5	18.1 ± 0.8	17.8 ± 1.1

Table 4: Normal values of total serum proteins, albumin, globulin, glucose and enzymes of goat (according to different authors)

Authors and Parameters	Total serum protein g/dl	Albumin g/dl	Globulin g/dl	Glucose g/dl	SGPT Unit/L	SGOT Unit/L
Harvey (1962)	6.67	3.96	2.71	50		
Swenson (1977)	6.67	3.96	2.71	45-60		
Sastry (1983)	6.25					
Coles (1986)	6.25	3.95	2.30			
Plumb (1999)	6.4 - 7.8	2.4 - 4.4		60–100		
Feldman *et al.* (2000)	6.0-7.5					
Daramola *et al.* (2005)	7.1 ± 0.1				8.9±0.9	20.9 ±1.2
Olaifa & Opara(2011)	6.3-8.5	2.3-3.6	2.7-4.4		15.3-52.3	12-38
Sultana *et al.* (2011)	8.02 ± 0.22	3.03± 0.13	4.99± 0.23		15.96 ± 1.04	57.50±2.18

2.2 Effect of castration and exogenous testosterone on blood parameters and serum biochemistry of goat

Castration is removal of testis, or testicles, of male animals. Animals have been castrated to eliminate breeding and reduce aggressive behavior (Stafford, 2007). In the adult, red blood corpuscles, white blood cells, and blood platelets are formed in the bone marrow, and in the fetus, blood cells are also formed in the liver and spleen. The relationship between the endocrine system and hemopoiesis has been known for more than half a century, hypopituitarism is often accompanied by normochromic and normocytic anemia. Androgen and thyroid hormones are known to stimulate erythropoiesis (Sohmiya and Kato, 2005). Erythropoietin is secreted mainly from the peritubular endothelia and interstitial fibroblasts of renal tubules. It is also secreted partly from the liver in fetal rats and sheep, placenta, and astrocytes in the brain. The liver is the primary site of erythropoietin production in the fetus, and extra renal erythropoietin production was increased in anemic rats. In adult rats, erythropoietin is secreted mainly from the kidney, suggesting that some mechanism switches erythropoietin secretion from the liver to the kidney. This functional switching mechanism has yet to be fully elucidated. Fetal hypoxemia experiments showed that the erythropoitin secretion from the placenta was increased by hypoxic stimuli (Davis *et al.,* 2003).

The exogenous or endogenous testosterone reaches the androgen receptor usually after conversion into dihydrotestosterone in specific target tissues, whereas the same steroid can also act as an estrogen precursor when transformed by aromatase (Barbara *et al.,* 2006). In animal subjected to orchiectomy, varying degree of hypertrophy have often been observed, even involving non-reproductive organs, Liver hypertrophy appear particularly interesting in view of the metabolic alterations that's could possible ensue (Vizzotto *et al*., 1995). The effects of castration were revealed by a reduction of the volume of hepatocytes associated with a reduction of the sinusoidal bed. Such reduction is corresponding associated with an increase of extrapranchymal components (endothelia Glisson capsule) (Vizzotto *et al*., 1995). Other study demonstrated that in male rats, long term castration causes an increase in sensitivity to estradiol as measured by induction of progesterone receptor m-RNA (PRmRNA) in ventromedial hypothalamus (Wennstrom and Crews, 1998). Low plasma testosterone levels are associated with hyperinsulinemia and glucose intolerance (Tchernof *et al.,* 1997).

Leblanc *et al.* (2004) suggest that both androgens and estrogens are important, but differential, regulators of lipid metabolism. Also suggest that quantities as well as the relative proportion of androgens and estrogens are important factor in the regulation of the plasma lipid profile, both androgen and estrogen deprivations are probably responsible for the unfavorable lipid profile in the castrated animals. It is, in fact, known that dehydroepiandrosterone is mainly transformed into androgens in the peripheral tissues in the rat (Sourla *et al.,* 1998). The physiological effects of sex steroids hormone on peripheral tissues are mediated though both intracrine and classical endocrine pathways (Leblanc *et al.,* 2004).

Hassan (2010) studied the effect of castration and testosterone hormone on some physiological aspect in rats and provides novel information on the role of castration and testosterone hormone replacement in the blood parameters in rats. Castration of the rats caused a significant decrease in red blood corpuscles, hemoglobin (Hb) concentration and packed cell volume (PCV); accompanied with significant increased mean corpuscular volume (MCV), mean corpuscular hemoglobin (MCH), total number of leucocytes, and percentage of neutrophils and low percentage of lymphocytes compared with control group. Treatment with testosterone hormone caused significant increased in red blood corpuscles, hemoglobin concentration and packed cells volume and significant decreased in total number of leucocytes, neutrophils and increased in the number of lymphocytes. The study showed a significant increase in the levels of total cholesterol, triglycerides, low density lipoprotein in castrated rats group compared with control value. Administration of testosterone hormone caused significant decreased in the levels of total cholesterol (TC), triglycerides (TG), and low density lipoproteins (LDL) compared with castrated rats group. The study showed no significant differences between groups in mean corpuscular hemoglobin concentration (MCHC), high density lipoproteins (HDL), total protein, albumin, globulin, glucose, alanineaminotrasferase enzyme activity and body weights. He concluded that castration of the rats produced significant effects in certain blood constituent and lipid profile. Moreover administration of testosterone hormone reversed the adverse effects caused by castration.

Zha *et al.* (2013) studied the effect of testosterone undecanoate on hematological profiles, blood lipid and viscosity and plasma testosterone level in castrated rabbits. Castration significantly increased the levels of TC, TG, HDL-C and LDL-C, but decreased hematocrit (Hct), and Hb. In the testosterone undecanoate (TU) injection group, whole

blood viscosity was markedly decreased in all share rates, whereas the fibrinogen (FBN) level wasincreased. Hb and Hct showed a tendency for higher concentration at 6 weeks.

Tikkanen and Nikkila (1987) and Bai and Kurup (1976) studied the effect of testosterone (sex steroid) on hepatic lipase and serum lipoproteins and concluded that castration significantly increased TC, TG, HDL-C and LDL-C levels and may be attributed to the decrease of hepatic lipase (HL) and lipoprotein lipase (LPL) activities due to the absence of gonadal hormones.

Cardiovascular complications are a well recognized side-effect of antihormonal therapy in men with prostatic carcinoma. Moorjani *et al.* (1988) studied changes in plasma lipoproteins in patients with prostate cancer during treatment with several androgen suppression therapies. Orchiectomy (removal of testis) caused hypercholesterolemia and an increase in both total and LDL apolipoprotein B, all of which are strong determinants of cardiovascular disease. The high density lipoprotein (HDL) concentration was not affected despite a reduction in plasma testosterone, perhaps due to a simultaneous decrease in estradiol.

Jockenhövel *et al.* (1999) studied the influence of various modes of androgen substitution on serum lipids and lipoproteins in hypogonadal men and concluded that androgen substitution increased TC, LDL-C, and TG and decreased HDL-C.

Hussein *et al.* (1999) conducted an experiment to determine the effects of castration on some metabolic alterations concerning proteins, lipids and minerals metabolism in both immature and mature rabbits. Castration caused a significant decrease in serum total protein, albumin, alpha 1-globulins and alpha 2-globulins concentrations. Meanwhile, gamma-globulins level was decreased temporarily at 2 weeks after castration in mature rabbits and beta-globulins level revealed non significant decrease at 2 weeks after castration in immature rabbits followed by a non significant increase. In mature rabbits beta-globulins level non significantly increased. A significant decrease in serum total nucleic acid concentrations was observed after castration throughout the experimental periods, whereas the value of serum uric acid level markedly increased after castration. Serum lipids concentrations (total lipids, total cholesterol, phospholipids and non esterified fatty acids) were increased after castration. Testosterone propionate administration in mature castrated rabbits restored most of the investigated serum blood parameters to the levels of intact non castrated mature rabbit. It could be concluded that castration (deficiency of testosterone) induced marked decrease in protein synthesis and

increased protein degradation, but serum lipids markedly elevated after castration in both immature and mature animals.

Olaifa and Opara (2011) observed the response to the closed method of bilateral castration using Burdizzo castrator was investigated in six West African Dwarf (WAD) goats at the Teaching and Research Farm, University of Ibadan, Nigeria for 4 weeks. The haematological values showed no significant increase in PCV, Hb, RBC and other indices of measurement, but the WBC count showed a significant increase ($p<0.05$) upon castration and remained elevated until the 4th week when it returned to within a normal range. This study showed that bloodless castration had a milder effect on serum profiles and might be a safer alternative to surgical castration in WAD goats, especially where protein deficiencies or hepatocellular insufficiency exists.

AL-Zghoul *et al.* (2008) designed a study to evaluate the effects of surgical castration on cellular and some biochemical parameters of blood and peritoneal fluid in Awassi lambs. Following castration, the number of peripheral fluid white blood cells (WBC) and the percentage of neutrophils significantly increased ($p<0.05$) while the percentage oflymphocytes significantly decreased ($p<0.05$). The blood fibrinogen, urea, creatinine, glucose, ALP, AST and LDH concentrations significantly increased ($p<0.05$). However, TP concentrations did not change. In the peritoneal fluid analysis, the total WBC count and the percentage of neutrophils significantly increased ($p<0.05$) while the percentage of monocytes significantly decreased ($p<0.05$) following the operation. There was no significant change in the percentage of lymphocytes in the peritoneal fluid. The concentration of peritoneal fluid TP, urea, creatinine, glucose, ALP and AST significantly increased ($p<0.05$) while LDH concentration did not change. Results of this study show that changes in the blood and peritoneal fluid cellular and biochemical components are likely to follow elective surgical castration in lambs.

The effects of bilateral orchidectomy on serum protein and enzyme levels were investigated in 12 healthy West African Dwarf bucks over a 7-week period by Oyeyemi *et al.* (2000). Although the activity of alkaline phosphatase increased over the period, theincreases were not statistically significant. There was a significant drop ($p<0.05$) in the activity of Aspartate amino transferase in the last 2 weeks of the study while alanine transaminase and gamma glutamyl transferase showed variation, which were in some cases significant. There was a slight hypoproteinaemia, which was traceable mainly to the globulin fraction.

It is well known that the thymus plays an important role in the development and maintenance of a competent immune system. The thymus atrophies with age, a process that is accelerated after puberty when there is elevation of serum sex steroid levels. Windmill and Lee (1998) examined the effects of castration on the lymphocytes of the thymus, spleen and lymph nodes. They used a panel of commercial monoclonal antibodies against various T and B cell surface markers to investigate the post-castration histological alterations in the thymus, spleen and lymph nodes of male Sprague-Dawley rats. Castration of 5-week-old male rats produced a significant increase in thymic weight ($p< 0.05$) compared to age-matched intact animals. The major observations from that immunohistochemical studies were post-castration elevations in staining for total T cells (MRC OX 19 and W 3/13), CD8 cells (MRC OX 8), B cells (MRC OX 12 and MARK-1) and cells bearing activation markers such as IL-2 receptor (MRC OX 39), transferrin receptor (MRC OX 26) and major histocompatibility class II antigen (MRC OX 6). These data suggest that following castration there is an increase in the ability of lymphocytes to respond to activation. As a result, there are elevated numbers of immature thymocytes within the thymus that undergo differentiation/maturation and consequently produce an increase in peripheral T and B cells.

Increased red blood cell mass (erythrocytosis) is the most common adverse event associated with testosterone therapy in clinical practice and in testosterone trials (Bhasin *et al.,* 2010, Calof *et al.,* 2005). Historical studies in preclinical models had suggested that testosterone induces an erythropoiesis-stimulating factor, which was measured in these early studies by a bioassay using a polycythemic mouse model (Mirand *et al.,* 1965). In retrospect, this erythropoiesis-stimulating activity of plasma from testosterone-treated animals may not only have reflected the activity of erythropoietin (EPO) but may also have reflected other circulating factors that are regulated by testosterone and which modulate erythropoiesis or systemic iron bioavailability (Shahani *et al.,* 2009; Ganz and Nemeth, 2011). Testosterone increases erythropoietin production by hypertrophy of renal tissue, particularly in high doses (Fried and Gurney, 1968). Activation of androgen receptors in erythroid cells appears to be necessary for testosterone to develop an erythropoietic effect in the bone marrow (Malgor *et al.,* 1998).

Goldberg *et al.* (1985) studied the role of endogenous testosterone on the lipoprotein profile in man. Eight normal men received a long-acting gonadotropin releasing hormone analog (LHRHA) for 10 weeks by SC injection. Plasma testosterone levels were acutely

lowered below 1 ng/ml after 4 weeks of LHRHA treatment and remained depressed at this level for the duration of administration of the analog. There were prompt increases in total cholesterol [baseline vs. peak (milligrams per dl) mean +/- SEM, 177 +/- 18 vs. 208 +/- 22; P less than 0.005], apoprotein B (apo B; 69 +/- 12 vs. 97 +/- 13; P less than 0.05), HDL-cholesterol (23 +/- 2 vs. 33 +/- 2; P less than 0.005), and apo A-I (80 +/- 7 vs. 112 +/- 5; P less than 0.005), but not in apo A-II (40 +/- 3 vs. 40 +/- 4; P = NS) levels. The peaks occurred after 10 weeks of treatment and were followed by a fall in these values after discontinuing LHRHA. These changes were largely prevented in a second study (six men) in which LHRHA was administered together with im testosterone enanthate, which was given every 2 weeks. These results show that suppression of endogenous testosterone leads to increases in HDL and LDL, demonstrating that testosterone has an important effect on lipoprotein metabolism and plays a key role in defining the lipoprotein profile in men.

Testosterone serum levels may influence the lipoprotein metabolism and possibly atherogenic risk. Berg *et al.* (2002) investigated the effects of long-term testosterone supplementation in hypogonadal men on multiple lipoprotein markers. 18 Hypogonadal men were studied before and after 3, 6, and 18 (n = 7) months of treatment with testosterone enanthate. During treatment, serum testosterone and estradiol increased, reaching normal levels ($p < 0.0001$ and 0.003, respectively). This was associated with a decrease in HDL cholesterol (from 1.40 +/- 0.10 mmol/l to 1.22 +/- 0.08 mmol/l, $p < 0.001$) after six months at the expense of HDL2 cholesterol ($p < 0.01$), as well as apoprotein A1 (from 139 +/- 3.4 mg/dl to 126 +/- 3.0 mg/dl, $p < 0.005$). Hepatic lipase activity increased ($p < 0.05$) and correlated positively with testosterone ($r = 0.56$, $p < 0.02$) and negatively with HDL cholesterol ($r = -0.58$, $p<0.02$). Total and LDL cholesterol, triglycerides, and apoprotein B did not increase.

Uyanik *et al.* (1997) studied the beneficial effects of testosterone undecanoate on the lipoprotein profiles in healthy elderly men. After testosterone undecanoate (TU; 120 mg/d orally for 2 months) supplementation, serum total cholesterol (TC), low-density lipoprotein cholesterol (LDL-C), and estradiol (E2) levels decreased from 198 +/- 30.7 mg/dl to 174 +/- 41.9 mg/dl ($p < 0.05$), from 111 +/- 18.14 mg/dl to 87.9 +/- 29.4 mg/dl ($p < 0.01$), and from 86.2 +/- 16.9 pmol/l to 70.5 +/- 18 pmol/l ($p < 0.01$), respectively. Statistically significant differences were not observed in the serum triglyceride (TG), high-density lipoprotein cholesterol (HDL-C), and apolipoprotein (apo) A-1 and apo B

levels after TU treatment. They concluded that TU may be an effective drug for protecting coronary heart disease in healthy elderly men with lowered total and free testosterone levels. It may also have beneficial effects for sexual function and behavior.

Anderson *et al.* (1995) studied the effect of testosterone enanthate on serum lipoproteins in man. Sixty-three normal Caucasian men were administered intramuscular testosterone enanthate (TE) 200 mg i.m. weekly for 12 months as part of a male contraceptive trial. This dose of TE caused a 2.5-fold increase in trough serum testosterone concentrations. High density lipoprotein cholesterol (HDL-C) was significantly depressed from pretreatment concentration of 1.19 +/- 0.04 nmol/l to 1.03 +/- 0.04 mmol/l after 12 weeks of treatment, and remained suppressed for the duration of treatment ($p < 0.001$). There were no changes in serum concentration of total cholesterol (TC), low density lipoprotein cholesterol (LDL-C) or triglycerides (TG) during treatment, but the concentrations of TC and LDL-C were depressed at three months post-treatment. Meriggiola *et al.* (1995) also observed that testosterone enanthate at a dose of 200 mg/week decreased HDL-cholesterol levels in healthy men.

Tenover (1992) studied the effects of testosterone supplementation in the aging male. With intramuscular testosterone enanthate (TE; 100 mg weekly) treatment, there was a significant increase in hematocrit, a decline in total cholesterol and low density lipoprotein cholesterol, and a sustained increase in serum PSA levels. Placebo treatment led to no significant changes in any of these parameters. We conclude that short term (3 months) TE supplementation to healthy older men who have serum T levels near or below the lower limit of normal for young adult men results in an increase in lean body mass and possibly a decline in bone resorption, as assessed by urinary hydroxyproline excretion, with some effect on serum lipoproteins, hematological parameters, and PSA. The sustained stimulation of PSA and the increase in hematocrit that occur with physiological TE supplementation suggest that older men should be screened carefully and followed periodically throughout T therapy.

Aydilek and Aksakal (2005) studied the effects of testosterone on lipid peroxidation, lipid profiles and some coagulation parameters in rabbits. Testosterone administration decreased the level of high-density lipoprotein cholesterol (HDL-C), while castration increased this level ($p< 0.05$). Triglyceride (TG) and total cholesterol (TC) levels in the castration group were significantly higher ($p< 0.05$) than those in the testosterone group.

The ratio of HDL-C:low-density lipoprotein cholesterol (LDL-C) decreased, while TC:HDL-C ratio increased ($p < 0.05$) in the testosterone group. No significant differences were found in the LDL-C levels among groups. As a result, testosterone has exacerbating effect on atherosclerosis risk factors including lipid profile, FBN and coagulation system.

Tyagi *et al*. (1999) designed an experiment to evaluate the effects of long-term administration of testosterone enanthate (TE) on lipid and liver function parameters in rhesus monkeys maintained under controlled dietary conditions. High density lipoprotein cholesterol (HDL-C) levels decreased gradually whereas there was an increase in low density lipoprotein cholesterol (LDL-C) levels. Transaminase (SGOT and SGPT) levels were also increased following TE injections.

Gupta *et al*. (2008) examined the differentiation and proliferation of human mesenchymal stem cells (hMSCs) and preadipocytes in vitro in the presence of dihydrotestosterone (DHT). DHT inhibited the differentiation of hMSCs into adipocytes, as well as lipid accumulation in existing adipocytes. DHT also inhibited the maturation of preadipocytes into mature adipocytes. This was secondary to the downregulation of the adipogenic differentiation markers aP2, PPARγ, and C/EBPα. No difference was found in hMSC or preadipocyte proliferation in the presence of DHT, suggesting that DHT only inhibits the uptake of lipids into adipocytes and not other hMSC differentiation.

Testosterone has also been shown to reduce myocardial infarct size compared with that in subjects not treated with testosterone by modulating the myocardial K_{ATP} channel, enhancing vasodilation, improving lipid metabolism (Gupta *et al*., 2008).

A number of researchers have reported an inverse relationship between testosterone level and immune function that is mediated by corticosteroid. These data agree with studies that indicate the existence of trade-offs in energy and nutrient use between the immune and reproductive systems, particularly during times of stress. More recent studies suggest, however, that the decrease in some indicators of immune function in animals with high testosterone levels is due to immundoredistribution, rather than immunosuppression. According to the immunoredistribution hypothesis, during an immunochallenge leukocytes are redistributed to areas of injury or infection for more effective defense against pathogens. If redistribution does occur, then increases in testosterone level may be associated with increased, rather than decreased immunocompetence (www.campus.murraystate.edu).

Low-grade chronic inflammation is increasingly being implicated in cardiovascular disease (CVD) etiology and may represent an alternative pathway through which testosterone (TT) and sex hormone-binding globulin (SHBG) influence CVD risk. Brand *et al*. (2012) examined the associations between endogenous testosterone, SHBG and total and differential white blood cell (WBC) counts in men. Higher SHBG and TT levels were associated with lower WBC counts. After adjustment for age, BMI, smoking, physical activity and diabetes status, total WBC count decreased by 0.163 (95% CI -0.236; -0.091) and 0.102 (-0.170; -0.034) per standard deviation (SD) increase in SHBG and TT respectively. Associations of SHBG and TT with total WBC count were mainly accounted for by a lower granulocyte count (β coefficient=-0.132 (-0.194; -0.070) per SD increase in SHBG and β coefficient=-0.104 (-0.161; -0.046) per SD increase in TT). No associations between FT and total and differential WBC counts were found. They concluded that endogenous TT and SHBG levels are inversely associated with total WBC and granulocyte count in middle-aged and older men. Even though the underlying mechanism and causal directionality requires further exploration, these results support a link between hormonal status and low-grade inflammation.

Adult spring chinook salmon (*Oncorhynchus tshawytscha*) elaborate high plasma concentrations of testosterone during sexual maturation, and these levels of testosterone have been shown to reduce the salmonid immune response in vitro. Slater and Schreck (1997) designed a research to find out the mechanism of testosterone's immunosuppressive action has led to the characterization of an androgen receptor in salmonid leukocytes. They examined the specific effects that testosterone had on salmonid leukocytes. Direct counts of viable leukocytes after incubation with and without physiological levels of testosterone demonstrate a significant loss of leukocytes in cultures exposed to testosterone. At least 5 days of contact with testosterone was required to produce significant immunosuppression and addition of a 'conditioned media' (supernatant from proliferating lymphocytes not exposed to testosterone) did not reverse the immunosuppressive effects of testosterone. These data lead them to conclude that testosterone may exert its immunosuppressive effects by direct action on salmonid leukocytes, through the androgen receptor described, and that this action leads to the death of a significant number of these leukocytes.

Testosterone-induced increase in hemoglobin and hematocrit is associated with stimulation of erythropoietin (EPO) and reduced ferritin and hepcidin concentrations.

Testosterone stimulates erythropoiesis by stimulating EPO and recalibrating the set point of EPO in relation to hemoglobin and by increasing iron utilization for erythropoiesis (Bachman *et al.,* 2013).

2.3 Male accessory sex glands

Animal-reproductive-system, any of the organ systems by which animals reproduce. The role of reproduction is to provide for the continued existence of a species; it is the process by which living organisms duplicate themselves. Animals compete with other individuals in the environment to maintain themselves for a period of time sufficient to enable them to produce tissue nonessential to their own survival, but indispensable to the maintenance of the species. The additional tissue, reproductive tissue, usually becomes separated from the individual to form a new, independent organism. Accessory sex glands that are conspicuous outgrowths of the genital tract are almost uniquely mammalian. The major mammalian sex glands include the prostate, the bulbourethral, and the ampullary glands, and the seminal vesicles. All are outgrowths of the spermatic duct or of the urethra and all four occur in elephants and horses and in most moles, bats, rodents, rabbits, cattle, and primates. A few members of these groups like carnivores lack ampullary glands, or ampullary glands and seminal vesicles. Cetaceans (whales, porpoises) have only the prostate, as do some carnivores, including dogs, weasels, ferrets, and bears (http://www.britannica.com; Dellmann and Eurell, 1998).

The accessory male sex glands include the vesicular glands, the prostate and the bulbourethral (Cowper's) glands. The occurrence and development of these structures vary widely among species. Unlike mammals, birds, such as chicken and turkey, do not have accessory sex glands but rather secretory cells in the epithelium of the excurrent ducts that add products to the semen. Normal development and function of the accessory sex glands are controlled by testosterone, and the synergistic action of estrogens may also be required. In some species, testosterone must be converted to dihydrotestosterone to be physiologically active on the accessory glands (Dellmann and Eurell, 1998). The accessory glands contribute most of the volume to the ejaculate (Ashdown and Hafez, 1995; Campos, 2003). Sperm-coating antigens are also secretory products of the accessory sex glands (Dellmann and Eurell, 1998; Pineda and Dooley, 2003). The contribution of each gland to sperm volume varies among species, due to differences in gland size, and even absence of one, or more of them, in some species (Gonzalez, 2002).

The accessory sex glands are present in most mammals, but their function(s) have not yet been clearly defined. In the golden hamster, removal of all the glands or the ventral prostate alone have been shown to considerably reduce fertility, while the effect is milder if the ampullary glands only are removed. In this study, embryo development from the 5th to the 7th day after mating was examined. Structural and morphometric criteria such as cell number, cell density, embryo volume, volume fraction of proamniotic cavity further revealed that abnormalities can be demonstrated as early as day 5 in the embryos sired by males with the ventral prostate gland alone or all glands ablated. Twin implantation and deviation from normal implanted axis are also observed. This is likely to be attributed to attenuated cell proliferation, as indicated by proliferating cell antigen labeling and more necrotic cell death. Taken together, exposure of sperm to secretions of the male accessory sex glands in particular, the ventral prostate, is important for differentiation and multiplication of cells after the embryo has implanted (Jiang *et al.*, 2001).

In the past few decades, the male accessory sex organs have received much attention. Most studies have followed three directions: (1) the biochemical or structural changes of the accessory sex organs in relation to the mechanism of action of androgens (Brandes, 1974; Cavazos, 1975); (2) the etiology of pathological conditions of the accessory sex organs (Brandes, 1974; Hafez, 1976); and (3) analyses of the composition of seminal fluid (Brandes, 1974; Eliasson and Lindholmer, 1976). Whether and how much these accessory sex organs contribute individually to mammalian fertility, however, has received little attention until 1978. In 1979, Pang *et al.* studied to understand the role of the seminal vesicles and prostate glands on the fertility and fecundity and it is suggested that the seminal vesicles and possibly the prostate glands are important in the production of young in mice. In 1945, Blandau removed the coagulating gland and the seminal vesicle of rats and although copulation appeared normal, no young were produced.

Adebayo *et al.* (2009) investigated the gross morpho-metry and histology of the vesicular, the prostate and the bulbourethral glands of male greater cane rats (Thryonomys swinderianus Temminck). The morphometry revealed that there was no significant correlation between the weights of the accessory glands and the testes (prostate r2 = 0.05; vesicular r2 = 0.04; bulbourethral r2 = 0.03; $p < 0.05$), whereas there was a positive correlation between the weights of the accessory glands and the age of the animals (prostate r2 = 0.61; vesicular r2 = 0.62; bulbourethral r2 = 0.54; $p < 0.05$). These findings showed that age was a factor in the full development of the accessory glands.

The accessory genital glands are supplied by several branches arteries from internal pudendal artery that arises about the level of the lumbosacral articulation as the other terminal branch of the internal iliac (Dyce *et al.,* 1987).

Seminal Vesicles

The vesicular glands are present in all domestic animal species except the camel, dog and cat (Shively, 1982; Dyce *et al.,* 1987). The vesicular glands, also known as seminal vesicle, the largest of accessory sex glands, are paired, large, elongated saccular organs and contribute the bulk of seminal fluid. They lie on each side of the caudal part of the dorsal surface of the bladder, largely lateral to the ampullae of the deferent ducts and are covered by peritoneum of the genital fold except over their lateral edges. These glands are grossly lobulated, irregular, knobby organ and more or less solid with narrow branching lumina (Shively, 1982; Dyce *et al.,* 1987; Getty, 1975; Bacha and wood, 1990; Ghosh, 1995; Dyce *et al.,* 2002; Pineda and Dooley, 2003; Youngquist and Threlfall, 2007). The vesicular glands are paired of lobular glands that are easily identified because of their knobby appearance (Nickel *et al.,* 1973; Land and Robinson, 1985; Athure *et al.,* 1996).

Seminal vesicles, two elongated saclike glands that secrete their fluid contents into the ejaculatory ducts of some male mammals. The two seminal vesicles contribute approximately 60 percent of the fluids passed from the human male during ejaculation. In some mammals the capacity of the seminal vesicles is much larger; the boar, for example, may emit up to 50 times as much seminal fluid. Carnivores, marsupials, monotremes, and cetaceans do not have seminal vesicles. The secretion of the seminal vesicles constitutes the bulk of the seminal fluid (semen). It is a thick fluid that contains the sugar fructose, proteins, citric acid, inorganic phosphorus, potassium, and prostaglandins. Once this fluid joins the sperm in the ejaculatory duct, fructose acts as the main energy source for the sperm outside the body (http://www.britannica.com).

Archana *et al.* (2009) conducted a study on the vesicular glands of 30 entire pure male Gaddi goats from birth to 5yrs and 6 months of age, divided into three equal size groups of 10 animals in each viz; pre-pubertal (1day old to <18 months of age), pubertal (18 months to < 5years of age) and post-pubertal (>5 years) age groups. In new born kid the glands were small, white cord like. It became "?" shaped at 6 months and "S" shaped at 12 months of age. A significant growth in size and weight of gland occurred at 6 month, then up to 12 month and beyond it grew slowly. The average length, width and thickness of the

left vesicular gland were higher than the right gland. The secretory acini of the lobules were lined by pseudostratified ciliated columnar epithelium which contained A-tall columnar, B-basal and C-narrow columnar type of cells. The number per unit area and size of the gland increased with age significantly from birth in the prepubertal animals and up to puberty. In post-pubertal animals it did not grow significantly, rather the connective tissue elements were increased in the capsule (adventitia). The intralobular connective tissue however, decreased at the expense of growth of acini at all ages.

Histologically, the paired vesicular gland is a compound tubular or tubuloalveolar gland (bulls, rams and bucks). The glandular epithelium is pseudostratified with tall columnar cells and small, spherical, often sparse basal cells. The secretory columnar cells have small lipid droplets and glycogen and give a positive alkaline phosphatase reaction. Some of the columnar cells possess light, bleblike projections. The epithelium of the vesicular gland of bucks is considerably higher during the breeding season than during nonbreeding season. The intralobular and main secretory ducts are lined by a simple cuboidal epithelium or by a stratified columnar epithelium in horses. The highly vascularized loose connective tissue of the propria submucosa is continuous with the dense connective tissue trabeculae, which may subdivide the organ into lobes and lobules. The interlobular septa are predominantly muscular, derived from the thick tunica muscularis, which is surrounded by a capsule of dense irregular connective tissue with a few smooth muscle cells. A tunica muscularis of varying width and arrangement surrounds the organ, followed by a tunica serosa and a tunica adventitia (Dellmann and Eurell, 1998).

Neves *et al.* (2013) studied the morphology and biometry of the vesicular gland of *Santa ines* breed sheep. The vesicular gland was constituted by a tube that was intensely wound around it, which is sectioned into different positions. Analyzing the tube, it was observed that the mucosa was highly folded with simple columnar epithelium with tall cells. The lamina propria was rich in elastic fibers and surrounded by a smooth muscle layer, which consisted of two laminas: an inner, constituted by circular fibers and an outer, with longitudinal fibers. The tunica adventitia showed loose connective tissue, typical and well-marked in some areas.

Mifune *et al.* (1986) examined the seminal vesicle epithelium of the mouse and golden hamster by light microscopy and by transmission and scanning electron microscopy. By transmission electron microscopy, in the seminal vesicle epithelium of both animals secretory epithelial cells which consisted of mostly light and a few dark cells were

observed. The epithelial cells possessed secretory granules which contained a densely stained core. The secretory granules in the mouse epithelium reacted weakly with periodic acid-Schiff (PAS) stain and were slightly stained with alcian blue (AB), and those in the golden hamster exhibited strongly positive reactions with PAS and AB. The nuclei in the mouse tissue were spherical or ovoid, and those in the golden hamster tissue had a few lobes. By scanning electron microscopy, the apical surfaces of most of the epithelial cells were commonly flat or domed, and those of some epithelial cells protruded into the lumen as apocrine-like processes, or possessed small and large orifices. Besides the epithelial cells, there were cells characterized by pseudopodium-like cytoplasmic projections, a few membranous structures, an irregular nucleus, and cytoplasm containing a few dense bodies, in the basal portions of the epithelial cells, or between the basal lamina and the epithelial cells. These cells of the two species were similar in their features.

Mollineau *et al.* (2009) studied the gross and micro anatomy of the seminal vesicles of male agouti (*Dasyprocta leporina*). The seminal vesicles of the agouti are lobulated structures. The mean diameter of the large lumen is 883.6 +/- 76.83 microm. The mucosa (24.1 +/- 0.92 microm), which is lined by pseudo-stratified columnar epithelium is thrown into folds, which often branch. The lamina muscularis mucosa is thin and is made of loose connective tissue containing blood vessels. The mucosa of the leaf-like coagulating glands of the agouti is folded. The mean diameter of the lumen is 488.3 +/- 41.96 microm. The mucosa contains tubuloalveolar glands, which have a mean length of 199.5 +/- 28.83 microm. The thin epithelium, 15.0 +/- 1.25-microm wide, consists mostly of pseudo-stratified columnar cells. The epithelium also has surface modifications in the form of apical blebs and cilia.

The vesicular gland mucosa of men reported by Hib (2003) had a pseudostratified epithelium with high non-ciliated columnar cells, basal and oval cells. The lamina propria was surrounded by two layers of smooth muscle cells, an inner circular and an outer longitudinal one. Also, the muscle layers were surrounded by loose connective tissue, which are rich in elastic fibers that constituted the adventitia.

Khalaf and Merhish (2010) conducted the anatomical Study of the Accessory Genital Glands in Goats (*Caprus hircus*) (in local Iraqi breeds). The seminal vesicle glands in bucks had mean length 3.61±0.01cm, mean width 2.44±0.01cm, mean weight 4.18±0.15gms mean volume 3.05±0.04 cm3.

To check the efficacy of immunocastration on the slaughter line, Bonneau (2010) used the seminal vesicle and claimed that accessory sex glands also an effective tool to measure the efficacy of immunocastration.

Prostate Gland

Prostate gland has a major contribution in the seminal fluid which plays important role in male fertility. Its functional significance lies in neutralizing the seminal plasma and to initiate active movement of the ejaculated spermatozoa (Hafez, 1987).

The prostate gland is consists of only the pars dessiminate in small ruminants extends along the whole length of the pelvic urethra but diminishes in thickness when followed caudally; most lies dorsal to the lumen. But the prostate of bulls (unlike those of small ruminants) has a second, compact part (body) consisting of paired lobes that have broken through the aponeurosis of the urethralis. These form a narrow bar across the first part of the urethra (Getty, 1975; Ghosh, 1995; Dyce *et al.,* 2002; Pineda and Dooley, 2003; Youngquist and Threlfall, 2007; Khalaf and Merhish, 2010).

Histologically, the prostate consists of a varying number of individual tubuloalveolar glands derived from the epithelium of the pelvic urethra. The prostate is seromucous gland except in dogs, where it is entirely serous (Bacha and Wood, 1990). Two portions may be distinguished, according more to topographic than to histologic features: the compact or external portion (corpus prostatae), and the disseminate or internal portion (pars disseminate prostatae). But the prostate glands in goats mostly comprised only of pars disseminate (Dellmann and Eurell, 1998; Pathak *et al.,* 2012). The external portion either entirely surrounds part of pelvic urethra at the level of the colliculus seminalis or covers part of its dorsal aspect (Dellmann and Eurell, 1998; Arthur, 1975; Dyce *et al.,* 2002). The disseminate portion is located in the propria-submucosa of the pelvic urethra. The secretory tubules, alveoli and intraglandular ducts of the prostate gland are lined by a simple cuboidal or columnar epithelium with occasional basal cells. The simple epithelium changes to stratified columnar or transitional epithelium toward the terminal portions of the ducts. The tall columnar cells possess microvilli and sometimes bleblike apical protrusions. The prostate is surrounded by a capsule of dense irregular connective tissue that contains smooth muscle cells around the internal portion, which is also surrounded by the striated urethral muscle (Dellmann and Eurell, 1998; Pathak *et al.,* 2012). Large trabeculae originate from the capsule and separate the external and internal portions into individual lobules. They are predominantly muscular in the external portion

of the gland. The thickness of trabeculae increased but interlobular and intralobular connective tissue decreased with increase in age (Pathak *et al.,* 2012). The external portion of the prostate gland of the bull is relatively inconspicuous and it is absent in small ruminants. The particularly well-developed internal portion encircles the urethra in bulls and bucks; in rams, it is U-shaped, and the midline of the ventral aspect of the urethra is free of glandular tissue (Bacha and Wood, 1990; Dellmann and Eurell, 1998). In dog the prostate is relatively large. It is yellowish in color, dense in structure, and lies at or near the anterior border of the pubis. It is globular and surrounds the neck of the bladder and the urethra at their junction (Berge, 1958; Smith, 1999; Evans and DeLahunta, 2004).

Mollineau *et al.* (2009) studied the gross and micro anatomy of the prostate gland of male agouti (*Dasyprocta leporina*). The epithelium of the agouti's lobulated prostate gland is also folded creating a large lumen with a mean diameter of 995.5 +/- 55.70 microm. The mucosa contains tubular and tubuloalveolar glands, each having a mean length of 134.4 +/- 13.59 microm. The epithelium (13.9 +/- 1.16 microm) consists of pseudo-stratified columnar cells.

Pathak *et al.* (2012) studied the postnatal development of the prostate gland of Gaddi goat from one day old to more than five years of age divided into three groups viz; prepubertal (1 day old to < 18 months of age), pubertal (18 months to < 5 yrs of age) and postpubertal (>5 yrs of age). The prostate comprised of corpus prostatae, a band like structure close to the junction of vesicular gland with the urethra, and the pars disseminate which extended in urethra well from its origin to the point of duct of bulbourethral gland. Microscopically, the corpus prostatae comprised of two compact glandular masses lying one over the other, dorsally over the origin of pelvic urethra covered by a thick fibro-reticular capsule. The gland composed of end pieces (luminated and non-luminated acini) and ducts arranged in lobulated fashion. The thickness of inter and intralobular connective tissue decreased with increased age at the expense of the growth of paraenchyma. With age the luminated secretory end pieces increased, while the non-luminatedend pieces decreased in the lobules of the gland. Glandular parenchyma were rich in mucous components by 6 month age serous and mucous components became almost equal and at 12 month age majority of the secretory end pieces turned in to serous type. The excretory ducts which were lined by stratified cuboidal epithelium in one day old kids changed to transitional epithelium in late prepubertal and pubertal animals.

Bulbourethral Glands

The mucous-secreting bulbourethral (Cowper's) glands are present in all domestic mammals except the dog (Bacha and Wood, 1990; Khalaf and Merhish, 2010). The bulbourethral glands are small, dorsoventrally flattened (Dyce *et al.,* 2002; Neves *et al.,* 2013) or round bodies (Pineda and Dooley, 2003) and situated on the dorsal surface of the urethra opposite the ischial arch (Getty, 1975; Ghosh, 1995; Neves *et al.,* 2013), closely related to the bulb of penis (Shively, 1982). They are largely covered by the thick and powerful bulbospongious muscle, and also by dense fibrous connective tissue and drain into the dorsal diverticulum. Their watery secretion is discharged before the main ejaculate and flushes the penile urethra in advance of the passage of the sperm-rich fraction (Getty, 1975; Youngquist and Threlfall, 2007; Neves *et al.,* 2013). Hemeida (1985) described the bulbourethral gland of balady buck were large, dense, spherical organs, 1.5 cm in diameter and 2 gm in weight.

Histologically, the paired bulbourethral gland is a compound tubular (boars, cats, bucks) or tubuloalveolar gland (bulls, rams, stallions) and absent in dogs. The secretory portions of the gland are lined with a tall simple columnar epithelium and occasional basal cells. They open into collecting ducts lined by a simple cuboidal or columnar epithelium, unite to form larger intraglandular ducts lined by a pseudostratified columnar epithelium. These, in turn, open into a single (or multiple) bulbourethral duct with a lining of transitional epithelium. The gland is ensheathed by a fibroelastic capsule containing a variable amount of striated muscle cells. Trabeculae, extending from the capsule, consist of dense irregular connective tissue and some smooth and striated muscle fibers. The interstitium consists of loose connective tissue and a few smooth muscle fibers but in bucks, smooth muscle cells are particularly abundant within the interstitium. In ruminants, the gland is surrounded by the bulbocavernous muscle (Dellmann and Eurell, 1998; Neves *et al.,* 2013).

Nielsen (1976) studied the bulbourethral gland of the rat, using ordinary light microscopy, electron microscopy and histochemistry. It is a lobular gland and, centrally in each lobe, there is a duct, the ampulla, into which the alveoli drain, either directly or via a very short and narrow ductule. In some glands all the alveoli are cyst-like dilated. The alveoli and ampullae are bounded by tall glandular cells with flattened basal nuclei. The cytoplasm is full of secretion granules. There is only one large secretory duct into which all the ampullae open and this leave the gland at one end. In the electron microscope the granules

can be seen to be surrounded by a unit membrane, but quite often several granules flow together in a large irregular mess. Some granules have dense corn-like structure, while others are quite light. A non-membrane bounded mass can often be seen in the luminal part of the cells. Myoepithelial cells can be seen around the secretory cells.

Neves *et al.* (2013) studied the morphology and biometry of the bulbourethral gland of *Santa Ines* breed sheep. The bulbourethral glands were classified as compound tubulo-acinar, with prismatic cells, acidophilic cytoplasm and rounded nucleus basalis. The duct system of this gland was lined by pseudostratified epithelium. The capsule was composed by dense connective tissue containing striated skeletal muscle. The capsular tissue presented septals components, constituted by the loose connective tissue of the lamina propria and occasionally by the diffuse lymphatic tissue.

Hib (2003) and Junqueira and Carneiro (2008) mentioned that histologically, the bulbourethral glands in humans are tubuloalveolar formations in pairs, with mucous-type cells and striated skeletal muscle in septa that separate their lobes.

Mollineau *et al.* (2009) studied the gross and micro anatomy of the bulbourethral gland of male agouti (*Dasyprocta leporina*). The pea-shaped bulbourethral gland (BG) of the agouti consists of convoluted tubular, mucous secretory units, which are irregularly shaped each with a mean length of 177.9 +/- 7.10 microm and a mean width of 63.5 +/- 3.97 microm. The BG of the agouti is ventro-lateral to the rectum and dorsally positioned to the pubic symphysis, and connected to the urethra by short ducts.

Khalaf and Merhish (2010) conducted the anatomical study of the accessory genital glands in goats (*Caprus hircus*) (in local Iraqi breeds). The bulbourethral gland had mean length 1.58±0.005 cm, mean width 1.46±0.006 cm, mean weight 3.23±0.11gms and mean volume 2.05±0.03 cm3.

2.4 Effect of castration and exogenous testosterone on male accessory sex glands

Testosterone is a steroid hormone that enters its target cells to exert its effects. Within target cells, testosterone is converted to dihydrotestosterone, which binds to intracellular receptors. In addition to supporting the maturation of spermatozoa within the testis, testosterone promotes the development and function of male accessory sex organs, cause development of secondary sex characteristics and promotes male sexual behaviour. Lack of lobido (sex drive) and inability of produce offspring are two of the most obvious effects

of castration and the resultant lack of testosterone. If an animal is castrated before puberty, many of the masculine secondary sex characteristics fail to develop. In addition, the accessory sex glands fail to develop normally if castration occurs early in life and they regress and become nonfunctional if castration occurs after sexual maturity (Frandson and Spurgeon, 1992).

Sexual development is an ordered process that begins at the moment of fertilization and terminates with the production and transfer of viable gametes. The formation of the male gonad depends upon genes located on both sex chromosomes and autosomes. Differentiation and growth of the male reproductive system is directed by the fetal testis through the production of a putative peptide which causes the regression of the Mullerian ducts and the secretion of testosterone which virilizes the Wolffian duct and thereby directs the differentiation of the internal accessory structures of reproduction. A third hormone, dihydrotestosterone, is synthesized intracellularly from testosterone within the urogenital sinus and tubercle. The action of this hormone controls the formation of the prostate and the external genitalia characteristic of the male phenotype. The postnatal growth of the testis and accessory sex tissues follows a characteristic curvilinear pattern with the most prominent increments coincident with the onset in testosterone production (Desjardins, 1978).

Baker (1927) found that the seminal vesicles, Cowper's glands and adrenals are smaller when castration was performed at 100 days than when done at 200 days, and there is little difference if castration is performed at 50 or 100 days. Bratzler *et al.* (1954) also claimed that the accessory sex gland weights of the delayed castrates were larger than those of early castrates and atrophy was extremely rapid after castration.

Raeside *et al.* (1997) studied the effects of castration on early postnatal development of male accessory sex glands in the domestic pig. In the neonatal pig there was a remarkable production of steroids by the testes for the first few weeks after birth. Several androgens and estrogens reached a peak at about one month of age. In order to gain an understanding of the significance of this early steroid secretion they examined the effect on accessory sex glands of removal of the testes before the peak in these compounds would have occurred. Pigs were castrated (n = 38) at 2-3 weeks of age, with littermates serving as intact controls (n = 33). Animals were killed at ages ranging from 4-12 weeks. Blood samples were taken and both bulbourethral (BU) and vesicular glands (VG) were

removed, as well as the testes of intact males. Testes weights (wt) increased fourfold, as did body wt for both intact and castrate males. Both BU and VG showed absolute increase in wt (3.5x and 5x respectively) in intact males, and each was about 2.8x greater than in castrates. Histological sections were markedly distinctive for both BU and VG between intact and castrate animals, and a lack of developmental changes in both glands was noted in the castrates. Their findings provide clear evidence of an influence of the testes on accessory sex glands in the early postnatal life of the pig.

The effects of combined administration of ethinylestradiol (E) and testosterone (T) were studied by Olamide *et al.* (2007) in castrated Sprague-Dawley rats. The hormones E and T were administered three times weekly on alternate days, subcutaneously in the inguinal region for 4 weeks, 30 days after castration. E- treated animals received injections of 3 g/kg body weight (B.W), T-treated animals received 30 mg/kg B.W., combined testosterone and ethinylestradiol (T & E) -treated animals received injections of 30 mg/kg B.W. of T and 2 g/kg B.W. of E. Control animals - were in two groups, castrated and intact both received injections of 5 ml/kg B.W. of normal saline. i) The T-treated prostate weight was significantly higher than in castrated control ($p<0.05$). (ii) The E- alone treated prostate weight was not significantly different from castrated control ($p<0.05$). iii) The combined T and E-treated prostate weight was significantly higher than in castrated control ($p<0.05$). Morphological findings: in the combined T and E treated, the amount of connective tissue was well marked, there was an increase in the thickness of the epithelium and the size of the oval acini, relative to T-alone treated or the intact control. E-alone did not elicit any appreciable effect on the prostate, different from the castrated control. This finding demonstrates a synergistic effect of E on the prostate when administered along with T and also suggests that E may be involved in the pathophysiology of the abnormal enlargement of prostate gland.

Androgen deprivation elicited by surgical or chemical castration induces apoptosis in the prostatic epithelium and the number of glandular cells is significantly reduced (a 66% decrease) (English *et al.,* 1987) and secretory activity is severely attenuated and alternatively, the prostatic enlargement occurs in the aging prostate. (Olamide *et al.,* 2007). The castration of experimental animals also induces prostatic atrophy that can be reversed by testosterone treatment (Huttunen *et al.,* 1981).

Castration promoted changes in the biometric measures of the accessory sex glands and they were lower in the castrated animals. Analyzing weight of the vesicular and bulbourethral glands, Martins (2006), Campos (2003) and Neves *et al.* (2013) observed a significant difference between experimental groups comparing castrated and non-castrated breed sheep. Neves *et al.* (2013) studied the values of length, width and height of the sheep (castrated and non-castrated) reproductive glands, there was significant difference between castrated and non-castrated animals. These results confirm the assertions of Nunes (1982) and Risbridger and Taylor (2006), who had observed the functional dependence of the reproductive accessory glands on testosterone, providing different biometric data of the respective glands analyzed after castration. The levels of testicular steroids during the period after the early postnatal peak seemed to have been sufficient to sustain development of the accessory sex glands (Desjardin and Jones, 1970; Jean-Faucher *et al.,* 1986) whereas Rudolph and Starnes (1954) also found the regression of the seminal vesicle and prostates in castrated rats.

Chinoy *et al.* (1974) studied the effects of castration, testosterone propionate (TP), and vasoligation on nucleoprotein levels in the accessory glands of guinea pigs and showed that castration caused a marked decrease in RNA in all accessory glands except the seminal vesicle, while TP treatment increased RNA to levels considerably above those of controls. Vasoligation had an effect similar to that of castration, but was lowered, in varying amounts, in the other accessory glands. TP treatment raised DNA levels above those of controls in all tissues. Protein concentrations were lowered in all glands of castrated animals except the seminal vesicle. TP treatment caused an increase in protein concentrations to levels raised protein levels in varying degrees, depending on surgical technique. These results indicate that nucleoprotein metabolism of the guinea-pig accessory sex glands is androgen dependent.

MATERIALS AND METHODS

3.1 Animals

Fifteen male goats (4 months old) were used in this experiment. The goats were purchased from the near local market and housed in a well ventilated house. The goats were administered with the board spectrum anthelmintic (Albencid®) to free them from parasites. The goats were divided into three groups; Group-A: goats (castrated), Group-B: control group and Group-C: goats with excess testosterone (exogenous IM administration of testosterone enanthate). Goats of group-A were castrated immediately after purchase and maintained post-operative hygienic care. Before 7 days of castration, goats were vaccinated with Vaxitet® (0.5 ml absorbed Tetanus Toxoid/buck, IM; Incepta Vaccine Limited, Dhaka) to prevent tetanus. Goats of group-C were administered testosterone enanthate (TE) (Testosterone Enanthate injection®, 250 mg/ml, Rotexmedica, Trittau, Germany) intramuscularly @ 125 mg/goat weekly for a period of 2 months.

The goats were purchased at mid-January, 2013 and after rearing of four months, the goats were slaughtered at mid-May, 2013.

3.2 Collection of blood samples

Befre slaughter, 7.5 mL of blood from each goat was collected by jugular venipuncture using a sterile needle and syringe. 5 mL of it was put into commercially prepared tubes containing EDTA as the anticoagulant, while 2.5 mL was put in separate tubes without an anticoagulant. The samples were taken before 10 am in the morning when the animals were calm and the ambient temperature was low. Thereafter, the samples were immediately taken to the laboratory for analyses.

3.3 Hematological analysis

The hematological analysis was carried out by Automated Mythic-22 Hematology Analyzer, Switzerland.

3.4 Biochemical analysis

The biochemical analysis was performed by HUMALYZER-2000, Germany. The glucose, protein and lipid profile were measured using end point method and serum enzyme (SGOP & SGPT) level was measured using kinetic method.

3.5 Anatomical study

After slaughter, the accessory sex glands (seminal vesicles, prostate glands and bulbourethral glands) were collected. The location and shape were observed and the length, width and weight of them were measured and preserved in Bouin's solutions immediately after slaughter.

3.6 Histological study

The selected samples were processed in the laboratory for histological studies following standard histological techniques, and the paraffin sections then cut at 6 µm thickness using microtome. After cutting, the sections were floated on luke-warm water in a floatation bath at 37°C for stretching, then the sections were attached on cleaned glass slides using egg albumin and dried on a hot plate of slide warmer boxes. The sections then were stained with routine Hematoxylin and Eosin stain (Gridley, 1960) for histomorphological study. After staining, the sections were rehydrated in descending grades of alcohol, cleared in xylene and mounted with "DPX". The stained sections of seminal vesicles, prostate glands and bulbourethral glands were studied thoroughly under compound microscope using 4, 10, 40 and 100 objectives.

3.7 Measurement

The capsular thickness of bulbourethral glands, thickness of lamina muscularis and adventitia of seminal vesicle and histological cross sectional length and width of the glandular secretory units of seminal vesicle and prostate glands were measured (at 10X) using calibrated scale by oculometer (12.5X).

3.8 Photography

The photographs of this study were taken from the studied slides with the help of OPTICA photo-microscope (B-350), Italy.

3.9 Statistical analyses

All data were analyzed by one–way analysis of variance (ANOVA). The specific group differences (I. between castrated and control; II. between control and testosterone treated group) were determined using student's *t*-test.

RESULT AND DISCUSSION

Testosterone, the principal androgen, exerts both androgenic effects involving growth stimulation and functional maintenance of the male reproductive tract and anabolic effects involving growth stimulation of nonreproductive organs, such as muscle, kidney and liver (Barbara *et al*., 2006) and also affects the hemogram of animals (Zha *et al.*, 2013; Bai and Kurup, 1976; Tyagi *et al*., 1999; Aydilek and Aksakal, 2005). Several non-genetic factors including castration affecting haematological parameters of farm animals have been observed (Carlson, 1996; Johnston and Morris, 1996; Svoboda *et al.,* 2005; Xie *et al.*, 2013). Blood is an important and reliable medium for assessing the health status of individual animals (Oduye, 1976). Haematological parameters are good indicators of the physiological status of animals (Khan and Zafar, 2005). The hematological tests served as information base for animal health assistance. To observe the effect of castration and exogenous testosterone administration on hemato-biochemical parameters and on male accessory sex glands, the male goats (n=15) were reared for four months for the desired treatment. After that, the blood collection for hematological and biochemical studies, gross anatomical studies were done and collected samples were used for further histological studies.

4.1 Effect of castration and exogenous testosterone on erythrocyte indices of goats

Castration of the goats caused a significant decrease in red blood corpuscles (RBC) and packed cell volume (PCV); accompanied with significant increased mean corpuscular volume (MCV) and mean corpuscular hemoglobin (MCH). Treatment with exogenous testosterone (TE, testosterone enanthate) hormone caused significant increased in RBC and PCV. Hemoglobin concentration insignificantly decreased in castrated goats and increased in testosterone treated goats. Both the castration and exogenous testosterone did not affect much the mean corpuscular hemoglobin concentration (MCHC) (Table 5). Though the values were changed both in castrated and TE treated goats, the values were within normal range according to different authors (Table 1). These findings corroborate the findings reported by Kelani and Durotoye, 2002; Hassan, 2010 and Zha *et al.,* 2013. Testosterone has the ability to increase erythropoiesis (red blood corpuscles production) in the kidneys, and a higher red blood corpuscles (RBCs) count may improve iron kinetic studies (Hassan, 2010).

Table 5: Values of red blood cell count, hemoglobin concentration, packed cells volume and erythrocyte indices of castrated, control and testosterone treated goats

Parameter	Red blood corpuscles $10^6\times/\mu l$	Hemoglobin (g/dl)	Packed cell volume %	MCV (fl)	MCH (pg)	MCHC (g/dl)
Castrated goats	7.18±0.44**	7.78±0.61	23.62±1.03*	32.71±1.13*	10.91±0.24*	32.91±0.42
Control goats	10.26±0.68	9.56±0.92	28.83±0.78	27.79±1.08	9.23±0.27	33.13±0.48
Testosterone treated goats	12.47±0.50*	11.09±1.05	32.50±0.95*	26.05±0.72	8.70±0.37	34.20±0.49

* $p<0.05$ and ** $p<0.01$ (*t*-test)

4.2 Effect of castration and exogenous testosterone on leucocytes indices of goats

The effect of castration and testosterone on leucocytes indices of goats of present study has been shown in Table 6. Total number of white blood cells (WBC) was increased in castrated goats but in TE treated goats, WBCs were significantly ($p<0.05$) reduced. In current study, there was a significant increase ($p<0.01$) in the percentage of number of neutrophils accompanied with a significant decrease ($p<0.01$) in the percentage of number of lymphocyte in castrated group. The reverse case was observed in TE treated group. The values of WBC and DLC (differential leukocyte count) of all three groups were within/ or near to normal range (Table 2). There were no major changes observed between groups (castrated, control and TE treated) in basophiles, eosinophils and monocytes count. The changes due to castration and TE administration made an agreement with the findings of Hassan, 2010; AL-Zghoul *et al.,* 2008.

Castration has been shown to elicit physiological stress, anti-inflammatory reactions (indicated by acute phase proteins), pain-associated behaviour, suppression of immune function, and a reduction in performance (Molony *et al.,* 1995; Fisher *et al.,* 1996 and 1997; Ahmed and Ahmed, 2011) to varying degrees. During castration, it is needed to fight infection that is performed by increased number of WBC. Surgical castration causes increased haptoglobin and decreased gamma-interferon production. Haptoglobin exerts a suppressive effect on lymphocyte function, and reduction of gamma-interferon results in suppression of the immune system's cell-mediated immunity and response to antigens and increases in neutrophil numbers and the neutrophil :lymphocyte ratio (Fisher *et al.,* 2001) or the possible increased in the white blood cells count which was accounted for mainly by changes in the number of neutrophils.

Androgens exert potent regulatory influence over the immune system, although the full nature of these effects and mechanism underlying hormone–induced changes in host immunity are poorly understood. Several observations indicate that sex hormones serve as important regulators of lymphopoisis. Thymic involution that occurs during puberty is associated with the onset of sex hormone production and can be delayed by castration

prior to puberty (Tartakovsky *et al.,* 1981; Thomas *et al.,* 2001). Castration of mice after puberty reverses thymic involution and leads to thymic hypertrophy, a process that can be reversed by replacement of androgen or estrogen (Tartakovsky *et al.,* 1981). The production of B lymphocyte is regulated by physiologic level of androgens (Thomas *et al.,* 2001).

Table 6: Total leukocyte and differential leukocyte values of castrated, control and testosterone treated goats

Parameter	White blood Cells $\times 10^3/\mu l$	Neutrophil %	Eosinophil %	Basophil %	Lymphocyte %	Monocyte %
Castrated goats	13.47±0.34	47.6±1.54**	3.6±0.50	0.6±0.24	46.2±1.24**	2.2±0.49
Control goats	12.06±0.56	36.6±0.81	4.6±0.50	0.6±0.24	55.4±1.72	2.4±0.51
Testosterone Treated goats	8.91±0.53*	31.6±1.63*	5.4±0.50	0.8±0.37	59.2±1.46	3.0±0.55

* $p < 0.05$ and ** $p < 0.01$ (*t*-test)

4.3 Effect of castration and exogenous testosterone on serum biochemistry of goats

Serum biochemistry has been found to be important and reliable means for assessing an animal's health status and might give an indication of the degree of damage to host tissue as well as severity of infection (Otesile *et al.*, 1991). The current study showed that the elimination of testicular androgens by castration results in a significant ($p<0.05$) increase in the levels of total cholesterol (TC), triglycerides (TG), low density lipoprotein (LDL) in castrated goats group compared with control value (Table 7). This result agree with Moorjani *et al.,* 1988; Jockenhövel *et al.,* 1999; Hassan, 2010 and suggest that the increase in plasma LDL is due to an increase in the number of LDL particles. The increase in the number of LDL particles in the present study could result from reduction LDL uptake by the LDL receptor (Wang *et al.,* 1993; Briggs *et al.,* 1996). Tikkanen and Nikkila (1987) and Bai and Kurup (1976) concluded that castration significantly increased TC, TG, HDL-C and LDL-C levels and may be attributed to the decrease of hepatic lipase (HL) and lipoprotein lipase (LPL) activities due to the absence of gonadal hormones.

One could argue that alteration in the plasma lipoprotein profile after castration could be the result to an increase in the secretion of hepatic very low density lipoprotein VLDL of cholesterol. Circulating VLDL particles are then catabolized into LDL cholesterol particles by the action of lipoprotein lipase (LPL). Furthermore, direct hepatic secretion of LDL incastration animals could explain the increase levels of plasma LDL, even through this metabolic pathway is not a major contributor to circulating LDL particles in normal animals. Androgen through surgical castration results in an atherogenic lipid profile (Xu *et al.,* 2003). It is also remarkable that after castration, androgens could

possibly favor their antagonistic effect on the action of estrogens on LDL receptor expression (Leblanc *et al.,* 2004).

Administration of testosterone hormone (TE) caused an insignificant decrease in the level of TC and a significant decrease ($p<0.05$) in the levels of TG and LDL compared with controlled group (Table 7). Total serum protein (TP) and albumin were significantly ($p<0.05$) reduced in castrated group and insignificantly raised in TE treated group. Serum glucose level was significantly ($p<0.01$) lowered in castrated group. The study showed no significant difference between groups in high density lipoproteins (HDL), globulin and in serum enzyme (SGOT and SGPT) level (Table 8). The values of WBC and DLC (differential leukocyte count) of all three groups were within or near to normal range (Table 3 & 4). The findings about serum biochemistry of the present study were similar to the findings of Meriggiola *et al.,* 1995; Tyagi *et al*., 1999; Jockenhövel *et al.,* 1999; Hussein *et al.,* 1999; Aydilek and Aksakal, 2005; Hassan, 2010. The majority of crosssectional studies have found a positive correlation of endogenous testosterone with HDL and a negative correlation with total cholesterol, LDL and triglycerides (Oppenheim *et al.,* 1989). Exogenous testosterone has been reported to increase the activity of hepatic lipoprotein lipase (LPL), an enzyme involved in HDL catabolism, therefore suggesting that testosterone treatment should reduce HDL levels (Zmuda *et al.,* 1993). Dihydrotestosterone (DHT) inhibited the differentiation of hMSCs into adipocytes, as well as lipid accumulation in existing adipocytes. DHT also inhibited the maturation of preadipocytes into mature adipocytes (Gupta *et al*., 2008).

The significant hypoproteinemia observed in castrated goats may be related to the immune status of the animal as well as a reduction in acute phase proteins, which are indicative of pain related stress in biological systems as reported by Molony *et al.* (1995). Testosterone has an important effect on lipoprotein metabolism and plays a key role in defining the lipoprotein profile (Goldberg *et al.*, 1985). Testosterone supplementation reduced visceral fat accumulation, improved fasting glucose levels, glucose tolerance, and mean arterial pressure, while having no statistically significant impact on total cholesterol or triglyceride levels (Herring *et al.,* 2013).

Table 7: Values of total serum cholesterol, triglyceride, high and low density lipoproteins of castrated, control and testosterone treated goats

Parameter	Cholesterol mg/dl	Triglyceride Mg/dl	High density Lipoproteins (HDL) mg/dl	Low density Lipoproteins (LDL) mg/dl
Castrated goats	84.67±3.76*	63.00±3.21*	35.00±1.53	31.00±3.51*
Control goats	67.33±3.38	44.33±1.45	40.33±2.08	17.66±1.45
Testosterone treated goats	58.33±2.60	32.67±2.60*	41.33±3.48	11.66±1.20*

* $p<0.05$ (*t*-test)

Table 8: Values of total serum proteins, albumin, globulin, glucose and enzymes of castrated, control and testosterone treated goats

Parameter	Total serum protein g/dl	Albumin g/dl	Globulin g/dl	Glucose g/dl	SGPT Unit/L	SGOT Unit/L
Castrated goats	4.71±0.23*	2.74±0.26*	1.97±0.15	49.77±1.83**	10.27±0.55	15.27±1.76
Control goats	6.66±0.26	3.91±0.14	2.75±0.36	70.23±2.71	11.21±0.37	16.73±0.75
Testosterone treated goats	7.13±0.20	4.11±0.19	3.01±0.08	81.87±3.29	13.35±0.55	20.80±1.38

* $p < 0.05$ and ** $p < 0.01$ (*t*-test)

4.4 Effect of castration and exogenous testosterone on male accessory sex glands

Male reproductive system consisted of the testis (the principle organ, the male gonad, the source of spermatozoa and also of male sex hormones called androgens), the excretory or ejaculatory ducts including the epididymis, the ductus deferentes (transport the spermatozoa from the testes to the exterior and allow their maturation on the way), the penis (the male copulatory organ) and accessory sex glands including the seminal vesicles, the prostate and the bulbourethral (Cowper's) glands (secrete fluids that help to form the seminal fluid and need to assure optium motility and fertility of spermatozoa) (Getty, 1975; Bacha and Wood, 1990; Ghosh, 1995; Dyce *et al.,* 2002; Archana *et al.,* 2009; Hafez, 1974; McDonald, 1980; Bone, 1988). Accessory sex glands were the important components of male genital system and play an important role in animal reproduction.

Anatomical study

Seminal vesicle

Seminal vesicles were the paired accessory sex glands in goats.

Location: The seminal vesicle or vesicular glands of all three groups (castrated, control, and testosterone treated) of goats were situated on the caudodorsal aspect (near to the neck) of the bladder and the initial part of the pelvic urethra, lateral to the ampullae of the ductus deferens (Fig 3 & 4). The present observations were similar to the Ghosh, 1995; Dyce *et al.,* 2002; Getty, 1975; Nickel *et al.,* 1973; Pineda and Dooley, 2003 and Youngquist and Threlfall, 2007. It was also found that the left vesicular gland was situated 2-3 mm caudal than the right one both in control and testosterone treated goats (Fig 3).

Size: The vesicular glands of same species were somewhat unsymmetrical in size (in length, width and weight) (Fig 5 & 6). Such a comment made by Getty, 1975 and Khalaf and Merhish, 2010. In present observation, the average length and width of the left vesicular glands were higher than the right glands that were similar to the findings of

Archana *et al.* (2009). It was also found a significant difference ($p<0.01$) on the length, width and weight of vesicular glands among three groups (castrated, control, and treated with exogenous testosterone) of goats in one way ANOVA analysis. The specific group difference (between castrated & control and between control & TE treated) was also observed in *t*-test (Table-9). Similar contentions regarding biometric values of male accessory sex glands have been held by earlier authors (Martins, 2006; Campos, 2003, and Neves *et al*., 2013) in different species of animals. The findings of this study provide clear evidence of an influence of the testosterone and castration on accessory sex glands in goats. Raeside *et al.* (1997) claimed the same.

Table 9. Length, width and weight of seminal vesicles in goats (mean ± SE)

Measurement of seminal vesicle	Castrated goats			Control goats			Goats treated with exogenous testosterone		
	Right Mean ± SE	Left Mean ± SE	General Mean ± SE	Right Mean ± SE	Left Mean ± SE	General Mean ± SE	Right Mean ± SE	Left Mean ± SE	General Mean ± SE
Length (cm)	1.077 ± 0.021	1.117 ± 0.035	1.097 ±0.030**	1.636 ± 0.015	1.667 ± 0.030	1.653 ± 0.025	1.840 ± 0.010	1.850 ± 0.041	1.850 ±0.026**
Width (cm)	0.632 ± 0.007	0.656 ± 0.011	0.647 ±0.011**	1.136 ± 0.015	1.160 ± 0.017	1.146 ± 0.015	1.190 ± 0.040	1.170 ± 0.015	1.183 ± 0.015*
Weight (gm)	0.886 ± 0.034	0.924 ± 0.028	0.904 ±0.031**	1.461 ± 0.041	1.511 ± 0.023	1.486 ± 0.010	1.828 ± 0.031	1.899 ± 0.073	1.860 ±0.057**

* $p<0.05$ and ** $p<0.01$ (*t*-test)

Shape: The vesicular glands were grossly lobulated, irregular and more or less solid. The present study identified the vesicular glands easily by their knobby or mulberry or glandular appearance (Fig 5 & 6). The observation has an agreement with Dyce *et al.,* 2002; Archana *et al.,* 2009; Nickel *et al.,* 1973; Land and Robinson, 1985 and Athure *et al.,* 1996 and is similar to the anatomical description of vesicular gland in bull by McDonald, 1980 and Bearden and Funguay, 2000.

Prostate gland

Prostate gland was the unpaired accessory sex glands in goats. Though, generally the prostate gland consists of two portions: the compact or external portion (corpus prostate) and the disseminate or internal portion (pars disseminata) (Fig 1 & 2), it consists of only pars disseminate in goats (bucks), which surrounds the pelvic urethra (Bacha and Wood, 1990; Getty, 1975; Dyce *et al.,* 2002; Arthur, 1975; Dellmann and Eurell, 1998; Pathak *et al.,* 2012). The present observation was the similar to the text as the corpus prostate didn't find in any goats of the present study that indicated that prostate gland of goats consisted only of pars disseminata. So, it was impossible for gross anatomical study but the samples from the dorsal portion of the pelvic urethra were collected for histological study.

Bulbourethral gland

The paired bulbourethral glands are present in all domestic mammalian species except the dog (Dyce *et al.,* 2002; Getty, 1975). It was consisted of right and left club-shaped independent lobes in all goats of present study, which lied on the dorsal surface of the caudal part of the pelvic urethra at the level of ischial arch under the covering of a layer of fibromuscular tissue and was closely related to the bulb of penis (Fig 3 & 4). The bulbourethral glands were well visible and somewhat round bodies. The current observation was similar to the Ghosh, 1995; Dyce *et al.,* 2002; Getty, 1975; Pineda and Dooley, 2003 and Shively, 1982.

The present study found a significant difference on anatomical parameters of bulbourethral glands among three groups of goats (Table 10) that was clear in the figure 3 and 4. The current results corroborate with the findings of Martins (2006), Campos (2003) and Neves *et al.* (2013). Analyzing weight of the vesicular and bulbourethral glands, they observed a significant difference between experimental groups comparing castrated and non-castrated breed sheep. Neves *et al.* (2013) studied the values of length, width and height of the sheep (castrated and non-castrated) reproductive glands, there was significant difference between castrated and non-castrated animals. These results confirm the assertions of Nunes (1982) and Risbridger and Taylor (2006), who had observed the functional dependence of the reproductive accessory glands on testosterone, providing different biometric data of the respective glands analyzed after castration. Rudolph and Starnes (1954) also found the regression of the seminal vesicle and prostates in rats.

Table 10. Length, width and weight of bulbourethral glands in goats (mean ± SE)

Measurement of bulbo-urethral gland	Castrated goats			Control goats			Goats treated with exogenous testosterone		
	Right Mean ± SE	Left Mean ± SE	General Mean ± SE	Right Mean ± SE	Left Mean ± SE	General Mean ± SE	Right Mean ± SE	Left Mean ± SE	General Mean ± SE
Length (cm)	0.567 ± 0.416	0.637 ± 0.015	0.602 ±0.028**	1.01 ± 0.043	1.09 ± 0.036	1.045 ± 0.037	1.07 ± 0.078	1.153 ± 0.030	1.112 ± 0.054
Width (cm)	0.483 ± 0.035	0.567 ± 0.05	0.525 ±0.043**	0.887 ± 0.076	0.973 ± 0.078	0.918 ± 0.042	0.933 ± 0.472	1.033 ± 0.07	0.983 ± 0.058
Weight (gm)	0.181 ± 0.013	0.215 ± 0.008	0.198 ±0.009**	0.490 ± 0.027	0.570 ± 0.032	0.537 ± 0.029	0.605 ± 0.028	0.665 ± 0.038	0.635 ± 0.030*

* $p < 0.05$ and ** $p < 0.01$ (*t*-test)

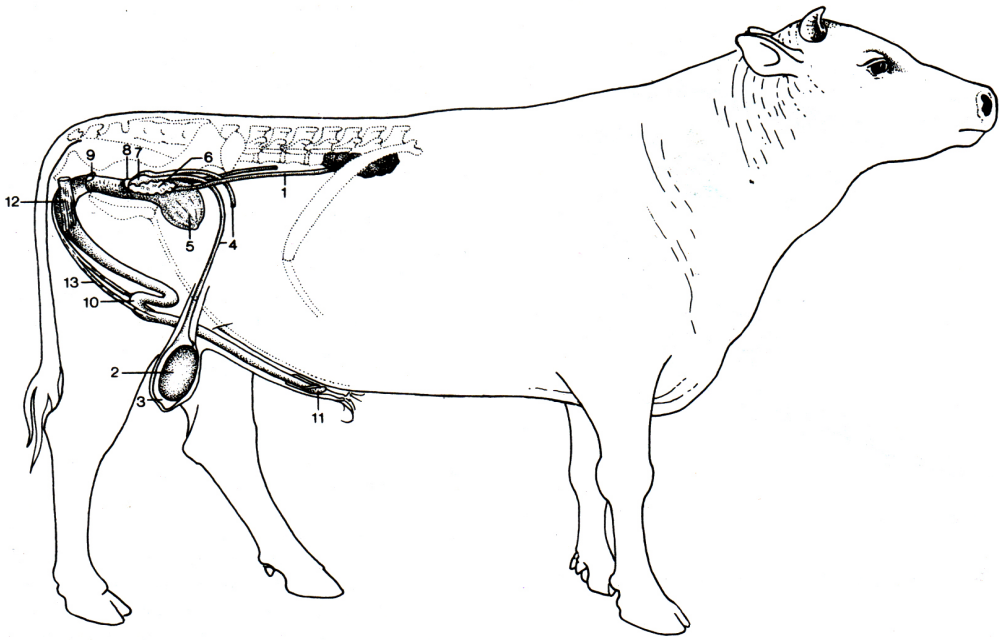

Fig 1. Schematic presentation of the urogenital organs of a bull (Position of the urogenital organs of buck is almost similar to bull). 1. Ureter; 2. right testis; 3. epididymis; 4. deferent duct; 5. bladder; 6. vesicular gland; 7. ampulla of deferent duct; 8. body of prostate; 9. bulbourethral gland; 10. sigmoid flexure of penis; 11. glans penis; 12. ischiocavernosus; 14. retractor penis (Textbook of Veterinary Anatomy by Dyce *et al.,* 2002. p. 715).

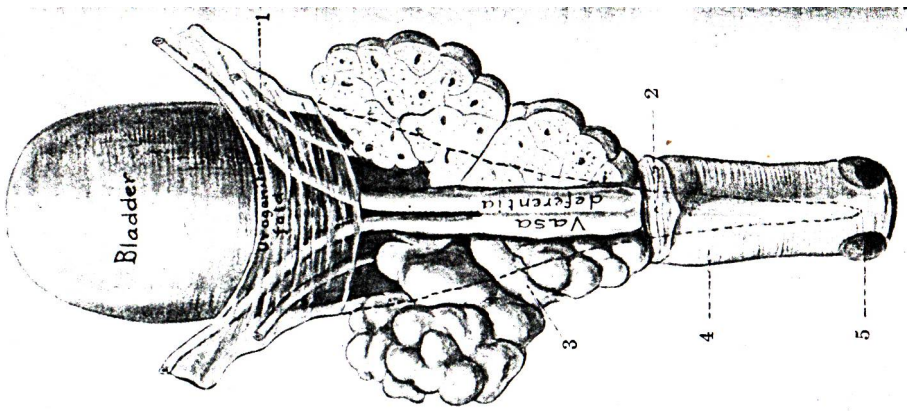

Fig 2. Schematic presentation of the internal genital organs of bull; dorsal view (Position of the genital organs of buck is almost similar to bull). 1. Ureter; 2. body of prostate; 3. vesicular gland; 4. urethra; 5. bulbourethral gland (The Sisson and Grossman's the Anatomy of the Domestic Animals by Getty, 1975. p. 942).

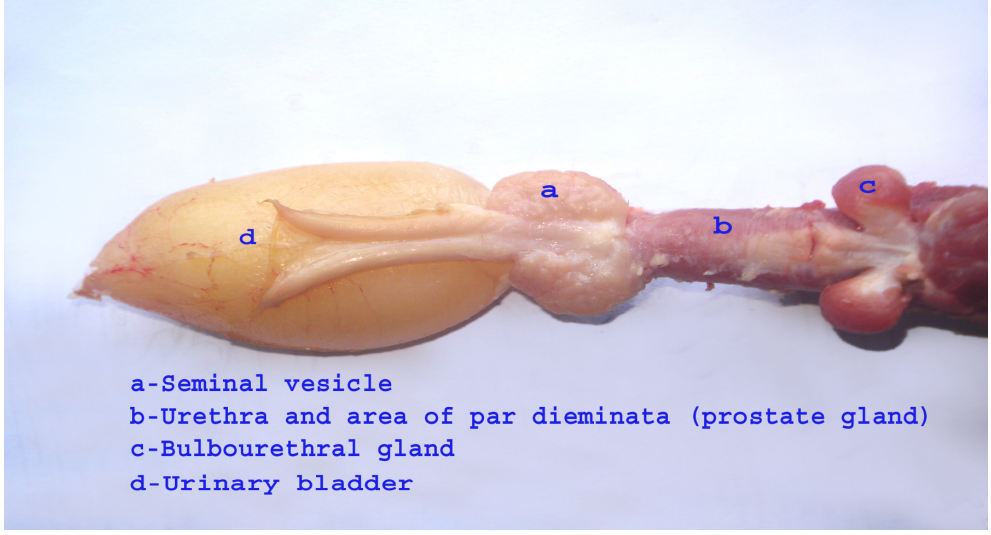

Fig 3. Accessory sex glands of goat (treated with exogenous testosterone)

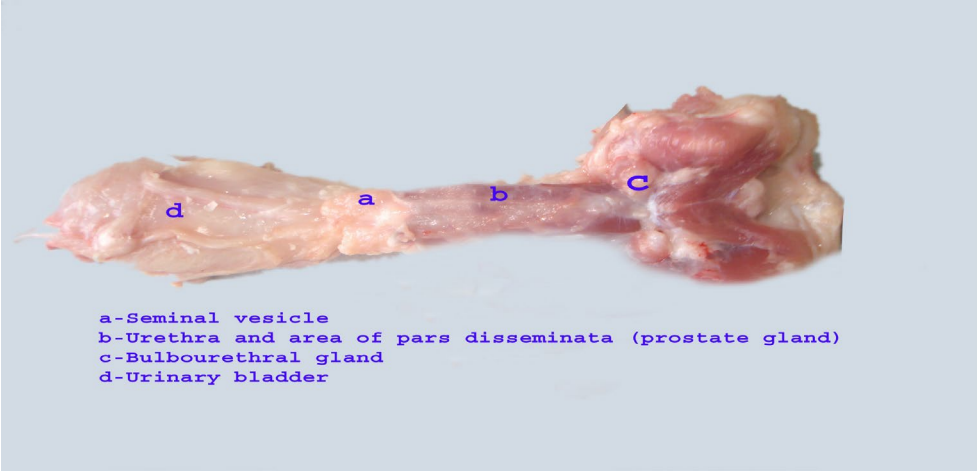

Fig 4. Accessory sex glands of goat (castrated)

Fig 5. Seminal vesicle of goat (treated with exogenous testosterone)

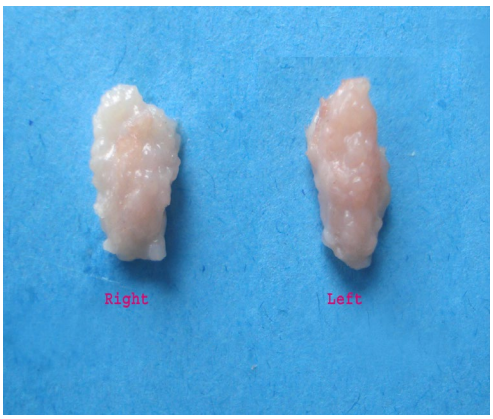

Fig 6. Seminal vesicle of goat (castrated)

Histological study

The Seminal Vesicle

Histologically, the vesicular gland of Black Bengal goats of all three groups was lobulated compound tubulo-alveolar gland similar as described by Sudhakar *et al*., 1986; Dellmann and Eurell, 1998 and Kundu, 1980. Each lobule of the gland showed folded tunica mucosa (comprising of lamina epithelialis and lamina propria), tunica propria submucosa, tunica muscularis and tunica adventitia (Fig 7-9). Similar description has been given by Trautmann & Fiebiger, 1957; Chandrapal, 1976; Dellmann and Wrobel, 1976; Sudhakar, 1982; Mollineau *et al.*, 2009 in other domestic animals. The mucosa was folded and the mucosa and the central collecting sinus of each lobule were lined with pseudostratified columnar epithelium containing tall columnar cells and small, spherical, often sparse basal cells. They contained eosinophilic cytoplasm and their nuclei were ovoid in shape (Fig 11-12). The present findings were similar to that of Dellmann and Eurell, 1998; Mifune *et al.*, 1986. It can be concluded that the tall columnar cells are the chief secretory cells and basal cells are the basal reserve cells. Similar contentions regarding these cells have been held by earlier authors (Cons, 1957; Chandrapal, 1976; Gupta 1989; Sudhakar, 1982) in different domestic animals.

The lamina propria-submucosa comprised of loose areolar connective tissue containing secretory end pieces with varying number of alveoli. The glandular tissue was highly reduced in castrated goats (Fig 10). Similar finding was described by Bacha and Wood, 1990. The glandular end pieces (secretory units) of the vesicular glands were lined by pseudostratified columnar epithelium. Occasionally, simple cuboidal or simple columnar epithelium was also encountered particularly when the alveoli were dilated. Similar to the epithelial lining of the mucosa, the glands also consisted of tall columnar type cells and short basal type cells (Fig 14-16). The cytological characters of these cells and their nuclei were almost similar to those as observed in the lining epithelium of tunica mucosa. The glandular or vesicular secretion was stored in the lumen of secretory units (Fig 13). It was also found that the myoepithelial cells were present around the secretory cells of glandular end pieces of seminal vesicle in all three groups of goats (Fig 14-16) that helped in the excretion of vesicular secretion. The intralobular and main secretory ducts were lined by a simple cuboidal epithelium (Fig 17). The highly vascularized loose connective tissue of the propria submucosa was continuous with the dense connective tissue trabeculae, which subdivided the organ into lobes and lobules. The interlobular septa were predominantly muscular, derived from the thick tunica muscularis, which was surrounded by a capsule of dense irregular connective tissue with a few smooth muscle

cells (Fig 7-9). The results corroborate with the findings of Dellmann and Eurell, 1998; Hib, 2003; Archana *et al.*, 2009; Neves *et al.*, 2013.

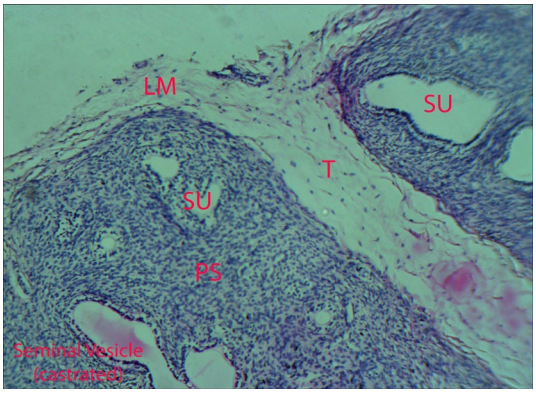

Fig 7. Cross section of seminal vesicle of castrated goats (10X); PS- Propria-submucosa, LM- Lamina Muscularis, A- Adventitia, SU- Secretory Unit, T- Trabeculae.

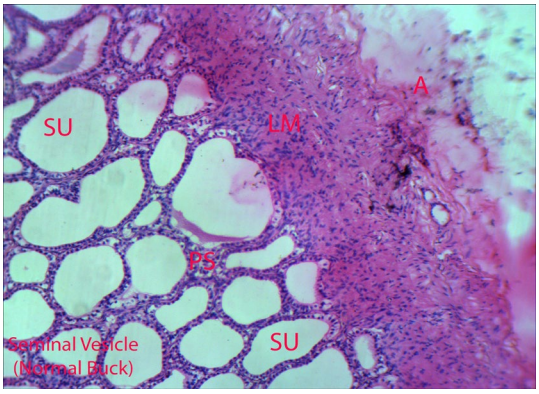

Fig 8. Cross section of seminal vesicle of control goats (10X); PS- Propria-submucosa, LM- Lamina Muscularis, A- Adventitia, SU- Secretory Unit, T- Trabeculae.

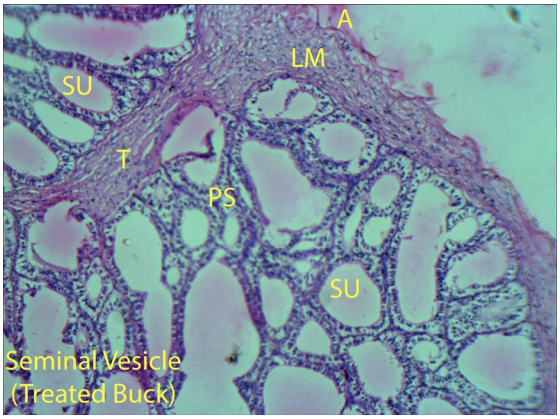

Fig 9. Cross section of seminal vesicle of goats treated with exogenous testosterone (10X); PS- Propria-submucosa, LM- Lamina Muscularis, A- Adventitia, SU- Secretory Unit, T- Trabeculae.

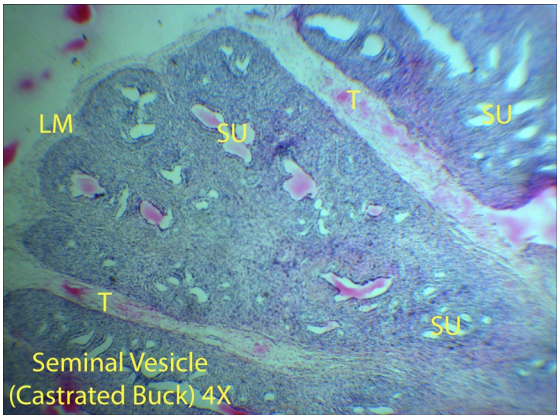

Fig 10. Cross section of seminal vesicle of castrated goats (4X). SU- Glandular Secretory Unit, PS- Propria-submucosa, LM- Lamina Muscularis, T- Trabeculae. The glandular tissue was highly reduced in castrated goats.

The tunica muscularis of varying width and arrangement, composed of a thick layer of interwoven (inner circular and outer longitudinal) smooth muscle fibers, surrounded the organ, followed by a tunica adventitia and the same pattern was observed in all groups of goats (Fig 7-9). Same architecture of tunica muscularis has been encountered by earlier authors (Dellmann and Eurell, 1998; Hib, 2003; Archana *et al.*, 2009) in different species of animals.

The tunica adventitia was comprised of loosely arranged meshwork of connective tissue fibers (Fig 7-9) as reported in goats (Gupta, 1978); sheep (Neves *et al.*, 2013); buffalo (Sudhakar *et al, 1986*) and in men (Hib, 2003). Many blood vessels and nerve fibers were seen in the tunica adventitia.

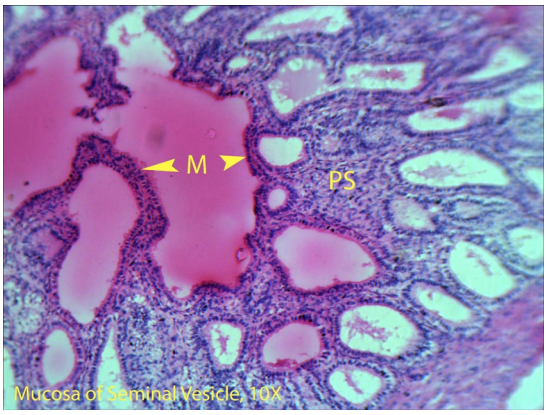

Fig 11. Mucosa of seminal vesicle (10X).
M- Folded mucosa, PS- Propria-submucosa.

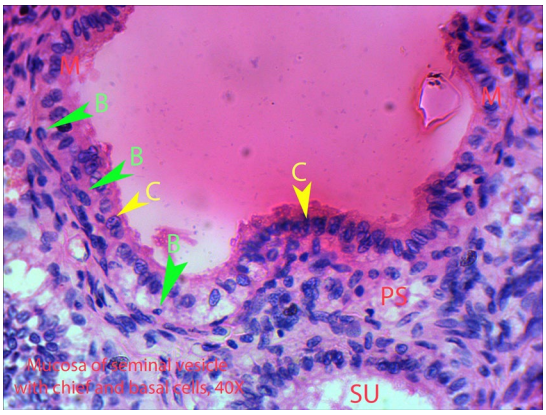

Fig 12. Mucosa of seminal vesicle (40X). M- Mucosa lined with pseudostratified columnar epithelium, PS- Propria-submucosa, SU- Secretory Unit, C- Chief secretory cell, B- Basal cell.

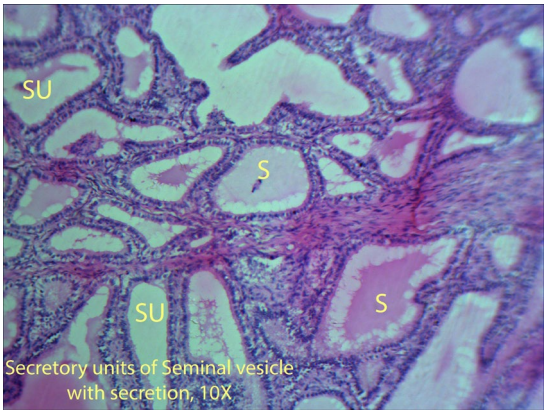

Fig 13. Glandular secretory unit of seminal vesicle with secretion (10X). SU- Secretory Unit, S- Vesicular Secretion.

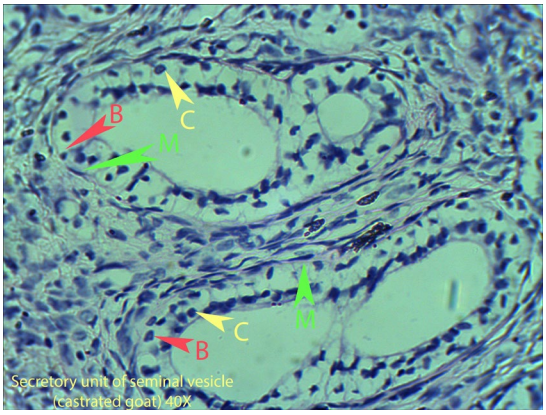

Fig 14. Glandular secretory unit of seminal vesicle of castrated goats (40X); B- Basal cell, C- Columnar cell, M- Myoepithelial cell that helps for excretion of vesicular or glandular secretion. The secretory unit was lined by pseudostratified columnar epithelium.

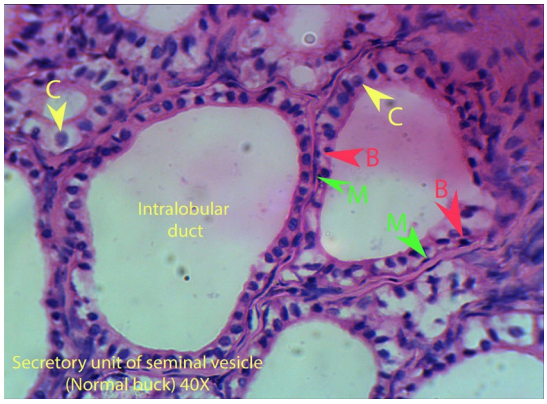

Fig 15. Glandular secretory unit of seminal vesicle of control goats (40X); B- Basal cell, C- Columnar cell, M- Myoepithelial cell that helps for excretion of vesicular or glandular secretion. The secretory unit was lined by pseudostratified columnar epithelium.

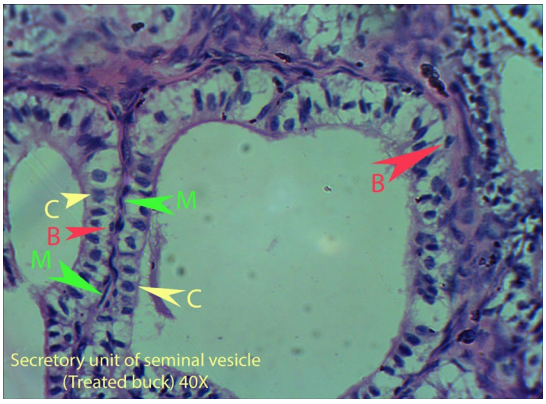

Fig 16. Glandular secretory unit of seminal vesicle of goats treated with exogenous testosterone (40X); B- Basal cell, C- Columnar cell, M- Myoepithelial cell. The secretory unit was lined by pseudostratified columnar epithelium.

Fig 17. Intralobular duct of seminal vesicle of goats (40X). SU- Glandular Secretory Unit. The duct was lined by simple cuboidal epithelium.

The study measured the thickness of tunica muscularis and adventitia (together) of seminal vesicle of all three groups of goats. The average thickness was 106.60 ± 16.82 µ in castrated goats; 117.00 ± 16.17 µ in control goats and 95.20 ± 8.04 µ in goats those were treated with exogenous testosterone (Table 11). It was also measured the length and width of glandular end piece (secretory units) of seminal vesicle of all three groups of goats. The average length and width were 108.60 ± 29.73 µ and 58.80 ± 7.00 µ respectively in castrated goats; 164.00 ± 48.64 µ and 96.20 ± 24.76 µ respectively in control goats and 232.60 ± 77.41 µ and 107.60 ± 32.41 µ respectively in goats those were treated with exogenous testosterone (Table 11). Though there was no statistically significant difference among the mean values of three groups, the length and width of secretory units of seminal vesicle were increased according to the increased level of testosterone. The findings of the present study supports the comments of Frandson and Spurgeon, 1992 and Raeside *et al.,* 1997 and it can be concluded that the castration and administration of exogenous testosterone affect the postnatal development of male accessory sex glands in Black Bengal goats.

Table-11: Measurement of lamina muscularis and adventitia and glandular secretory unit of seminal vesicle in goats (mean ± SE)

Parameters		Castrated goats Mean ± SE	Control goats Mean ± SE	Goats treated with exogenous testosterone, Mean ± SE
Thickness of lamina muscularis and adventitia (µ) n= 15		106.60 ± 16.82	117.00 ± 16.17	95.20 ± 8.04
Glandular secretory unit in propria-submucosa (µ) n=20	Length	108.60 ± 29.73	164.00 ± 48.64	232.60 ± 77.41
	Width	58.80 ± 7.00	96.20 ± 24.76	107.60 ± 32.41

The Prostate Gland

Histologically, the prostate consisted of a varying number of individual tubuloalveolar glands derived from the epithelium of the pelvic urethra. Generally the prostate consists of two portions: the compact or external portion (corpus prostatae), and the disseminate or internal portion (pars disseminate prostatae) in animals. As different text book descriptions, the corpus prostaticus does not occur in the small ruminants (Sisson, 1975; Dellmann and Wrobel, 1976). Further, Kundu (1980), Gupta and Singh (1982) and Gupta (1989) described only the pars disseminate in the goats. In present observation, only pars disseminata was found in all groups of goats (Fig 18-20). The result of present study corroborates with the findings of Sisson, 1975; Dellmann and Wrobel, 1976; Kundu, 1980; Gupta and Singh, 1982; Dyce *et al.,* 2002; Pineda and Dooley, 2003; Youngquist and Threlfall, 2007; Khalaf and Merhish, 2010; Dellmann and Eurell, 1998; Pathak *et al.,* 2012. Roy *et al.* (1985) also observed a small compact glandular mass embedded in the urethral muscle of ram and named it as corpus prostatae. The external portion of the prostate gland is absent in small ruminants. The particularly well-developed internal portion encircles the urethra in bulls and bucks; in rams, it is U-shaped, and the midline of the ventral aspect of the urethra is free of glandular tissue (Bacha and Wood, 1990; Dellmann and Eurell, 1998).

In the present study, the pars disseminata lay in the wall of the pelvic urethra as also reported by Aitken (1955). It was located mostly in the dorsal walls of urethra of all three groups of goats (Fig 18-20). This was in conformity with the description of Getty (1975), Ghosh (1995), Dyce *et al.* (2002), Pineda and Dooley (2003), Youngquist and Threlfall (2007) and Khalaf and Merhish (2010) who described it mostly lies dorsal to the lumen whereas Gupta and Singh (1982) described it mostly located in the ventral and lateral walls with only a few small lobules in the dorsal wall of urethra of male goats and Dellmann and Wrobel (1976) described it occurs all around (all sides) of the pelvic urethra in the propria of small ruminants.

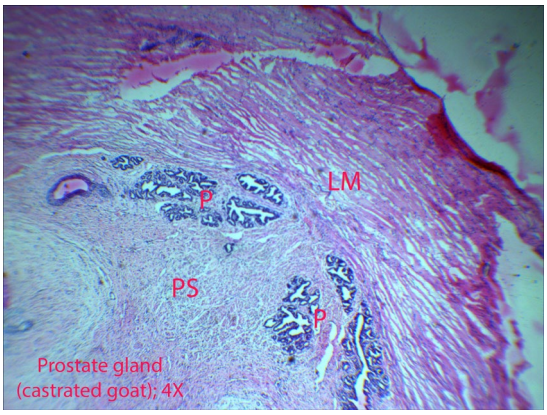

Fig 18. Location of prostate gland (pars dessiminata) of castrated goats (4X); PS- Propria-submucosa, LM- Lamina Muscularis, P- Prostate gland.

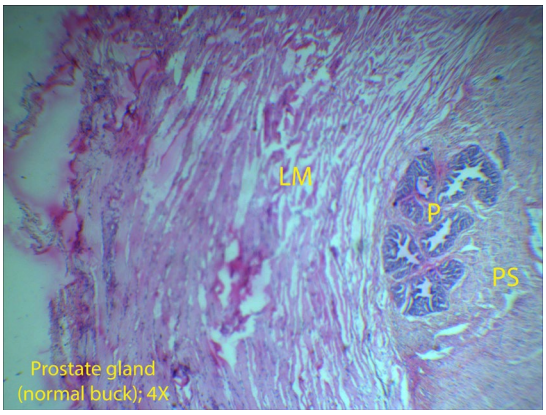

Fig 19. Location of prostate gland (pars dessiminata) of control goats (4X); PS- Propria-submucosa, LM- Lamina Muscularis, P- Prostate gland.

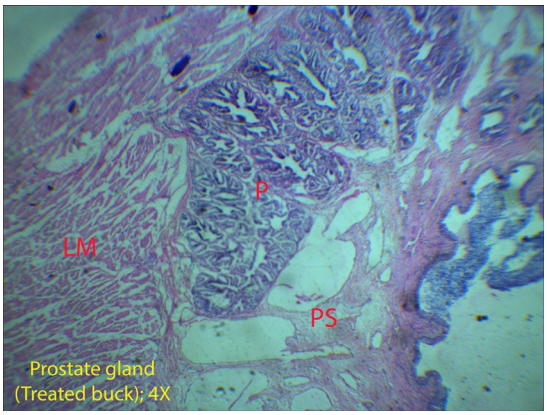

Fig 20. Location of prostate gland (pars dessiminata) of goats treated with exogenous testosterone (4X); PS- Propria-submucosa, LM- Lamina Muscularis, P- Prostate gland.

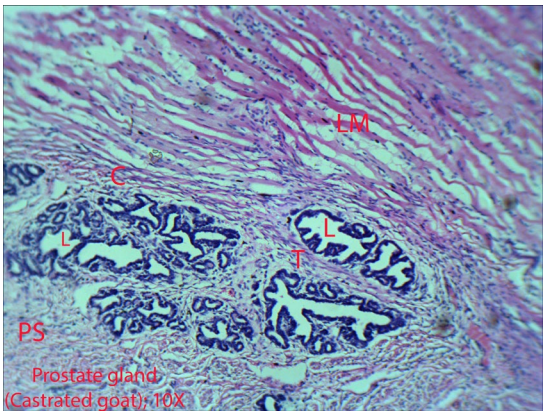

Fig 21. Cross section of prostate gland (pars dessiminata) of castrated goats (10X); C- Capsule, T- Trabeculae, L- Lobule, PS- Propria-submucosa, LM- Lamina Muscularis.

The disseminate portion, pars disseminata, was located in the propria-submucosa of the pelvic urethra (Fig 18-20). The pars disseminata lay in the urethral wall surrounded by its own capsule of loose connective tissue. A layer of skeletal urethral muscle surrounded the gland capsule from outside in all age groups. Large trabeculae originated from the capsule and separated the parenchyma into individual lobules (Fig 21-23). The findings of the present study corporate the findings of Dellmann and Eurell, 1998; Pathak *et al.,* 2012. The thickness of trabeculae increased but interlobular and intralobular connective tissue decreased with increase in age (Pathak *et al.,* 2012).

The parenchyma comprised of cisternae and ducts with luminated secretory end pieces. The epithelium showed a great variation in different glands and alveoli and even in a single alveolus. The secretory tubules, alveoli and intraglandular ducts of the prostate

gland were lined by a simple cuboidal to columnar epithelium with occasional basal cells (Fig 24). The cytoplasm contained secretion granules. This observation was supported by Kundu, 1980; Dellmann and Eurell, 1998; Pathak *et al.,* 2012. Aitken (1955) reported numerous compound tubules in the prostate. Yao and Eaton (1954) however, observed pseudostratified columnar epithelium lining the pars disseminate of Phillipine goats.

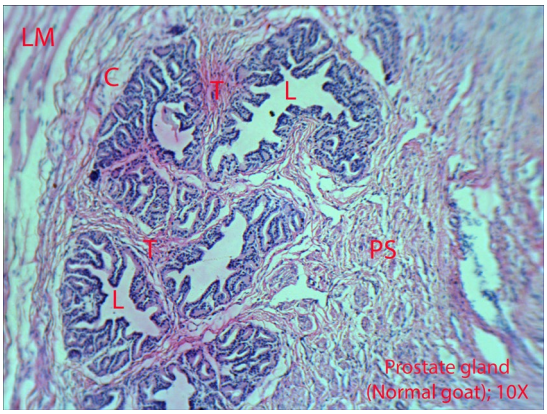

Fig 22. Cross section of prostate gland (pars dessiminata) of control goats (10X); C- Capsule, T-Trabeculae, L- Lobule, PS- Propria-submucosa, LM- Lamina Muscularis.

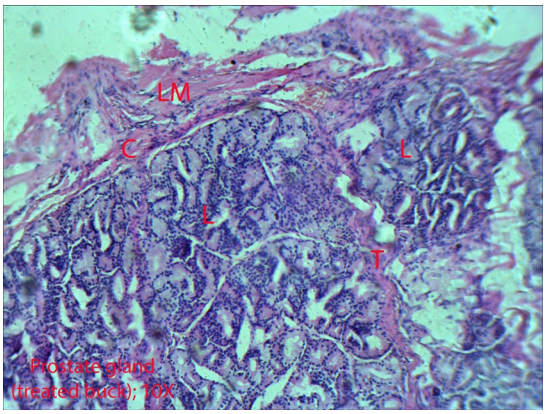

Fig 23. Cross section of prostate gland (pars dessiminata) of goats treated with exogenous testosterone (10X); C- Capsule, T- Trabeculae, L-Lobule, PS-Propria-submucosa, LM- Lamina Muscularis.

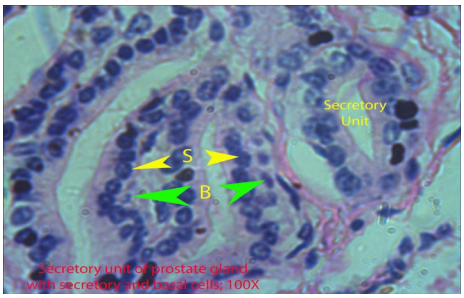

Fig 24. Secretory unit of prostate glands (pars dessiminata) of goats (100X). S- Secretory cell, B- Basal cell. The secretory unit was lined by simple cuboidal epithelium.

The study measured the length and width of lobules of prostate glands of all three groups of goats. The average length and width were 214.00 ± 49.88 µ and 102.80 ± 16.29 µ respectively in castrated goats; 392.00 ± 51.31 µ and 259.00 ± 29.26 µ respectively in control goats and 594.60 ± 60.88 µ and 345.00 ± 35.64 µ respectively in goats those were treated with exogenous testosterone (Table 12). The length and width of lobules of prostate glands of three different groups of goats were significantly different ($p<0.01$) in one way ANOVA analysis. The length and width of lobules of prostate glands of castrated goats were significantly decreased ($p<0.05$ and $p<0.01$ respectively in *t*-test) than the control goats. On the other hand, the length of lobules of prostate glands of goats those treated with exogenous testosterone significantly increased ($p<0.05$). The length and width of glandular secretory units of prostate glands of all three groups of goats were

also measured. The average length and width of secretory units of prostate glands were insignificantly increased or decreased according to the level of testosterone (Table 12). The findings of the present study supports the comments of Frandson and Spurgeon, 1992; Raeside *et al.,*1997; English *et al.,* 1987; Huttunen *et al.,* 1981 and Olamide *et al.,* 2007. Androgen deprivation elicited by surgical or chemical castration induces apoptosis in the prostatic epithelium and the number of glandular cells of prostate gland was significantly reduced (a 66% decrease) (English *et al.,* 1987). Huttunen *et al.* (1981) found prostatic atrophy in castrated experimental animals. Olamide *et al.* (2007) claimed that the prostatic enlargement occurs in the aging prostate (in increased level of testosterone).

Table 12. Measurement of lobule and glandular secretory unit of prostate gland in goats (mean ± SE)

Parameter		Castrated goats Mean ± SE	Control goats Mean ± SE	Goats treated with exogenous testosterone, Mean ± SE
Lobular measurement (μ) n=20	Length	214.00 ± 49.88*	392.00 ± 51.31	594.60 ± 60.88*
	Width	102.80 ± 16.29**	259.00 ± 29.26	345.00 ± 35.64
Glandular secretory unit (μ) n=20	Length	40.00 ± 11.04	106.20 ± 32.83	147.60 ± 56.09
	Width	23.00 ± 4.12	43.00 ± 11.26	50.40 ± 15.94

*p<0.05 and **p<0.01 (*t*-test)

Bulbourethral Glands

Histologically, the paired bulbourethral gland was a compound tubular in all three groups of goats. The findings were similar to earlier authors (Bacha and Wood, 1990; Dellmann and Eurell, 1998; Hib, 2003; Junqueira and Carneiro, 2008; Khalaf and Merhish, 2010; Neves *et al.,* 2013) as they described that the bulbourethral glands are compound tubular in boars, cats, bucks; tubuloalveolar gland in bulls, rams, stallions and in human and absent in dogs. The glands were surrounded by the bulbocavernous muscle (Fig 25-27) that is similar to other animals observed by Dellmann and Eurell, 1998; Neves *et al.,* 2013.

The secretory portions (secretory units) of the gland were irregular in size and shape in all three groups of goats and lined with a tall simple columnar epithelium and occasional basal cells. Most of the columnar cells were of the mucous type, with the nuclei basally placed and the cytoplasm contained the secretion granules (Fig 29). The intraglandular ducts were lined by a pseudostratified columnar epithelium (Fig 30). The gland was ensheathed by a capsule composed by dense connective tissue containing a variable amount of striated skeletal muscle. Trabeculae, extending from the capsule, also consisted of dense irregular connective tissue and skeletal muscle fibers. The interstitium consisted of loose connective tissue and smooth muscle fibers (Fig 28). These results

corroborate with the findings of Nielsen, 1976; Dellmann and Eurell, 1998; Mollineau *et al.,* 2009; Neves *et al.,* 2013.

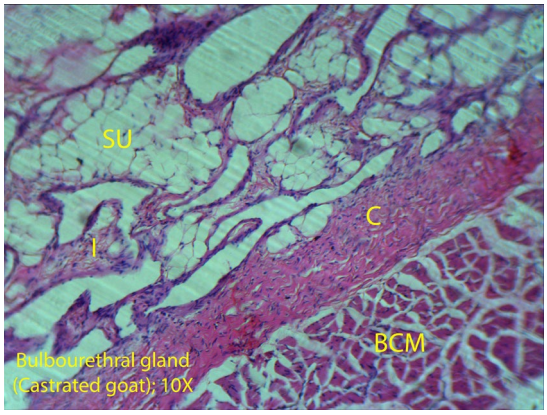

Fig 25. Cross section of bulbo-urethral gland of castrated goats (10X); BCM- Bulbocavernous muscle, C- Capsule, I- Interstitium, SU- Secretory Unit.

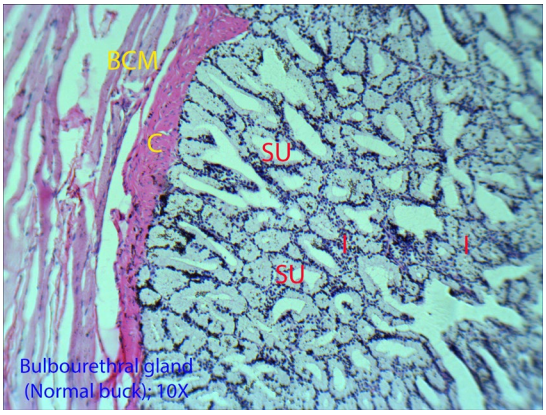

Fig 26. Cross section of bulbo-urethral gland of control goats (10X); BCM- Bulbocavernous muscle, C- Capsule, I- Interstitium, SU- Secretory Unit.

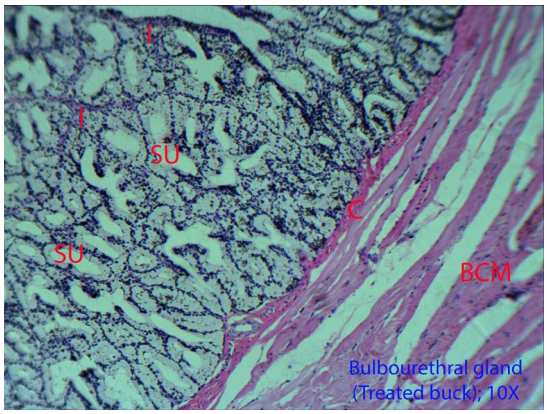

Fig 27. Cross section of bulbo-urethral gland of goats treated with exogenous testosterone (10X). BCM- Bulbocavernous muscle, C- Capsule, I- Interstitium, SU- Secretory Unit.

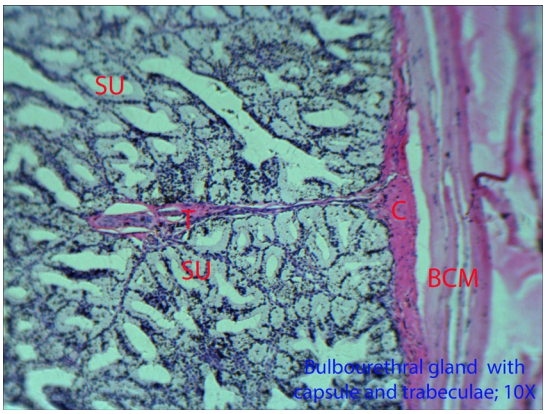

Fig 28. Capsule and trabeculae of bulbo-urethral gland of goats (10X). BCM- Bulbocavernous muscle, C- Capsule, T- Trabeculae, SU- Secretory Unit. The trabeculae contained skeletal muscle fibers.

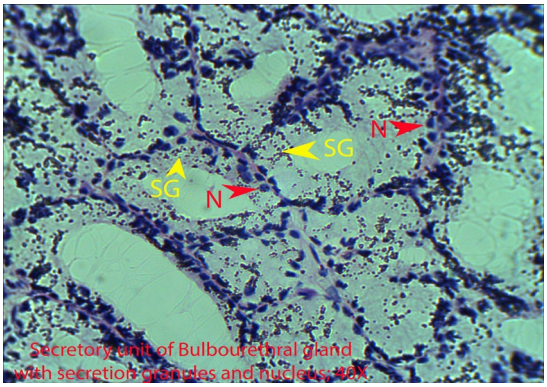

Fig 29. Secretory unit of bulbo-urethral glands of goats (40X). N- Nucleus, SG- Secretion granules. The secretory unit was lined by tall simple columnar epithelium. The nucleus was placed basally and the cytoplasm contained the secretion granules.

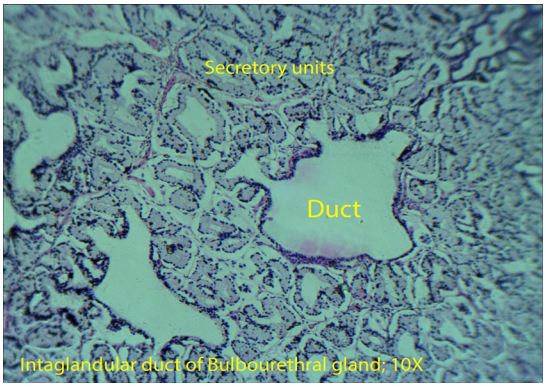

Fig 30. Intraglandular duct of bulbo-urethral glands of goats (10X). The duct was lined by pseudostratified columnar epithelium.

The study measured the capsular thickness of bulbourethral glands of all three groups of goats. The average thickness was 96.80 ± 9.93 μ in castrated goats; 76.00 ± 5.37 μ in control goats and 47.40 ± 7.47 μ in goats those were treated with exogenous testosterone (Table 13). There found a clear effect of castration and testosterone on bulbourethral glands of goats. The thickness of capsule of castrated goats (deficit testosterone) was insignificantly increased than the control goats whereas the thickness of capsule of goats those were treated with exogenous testosterone (excess testosterone) was significantly reduced ($p<0.05$). The findings of the present study support the comments of Frandson and Spurgeon, 1992 and Raeside *et al.,* 1997. The findings provided a clear evidence of an influence of castration and the presence of the testes (source of testosterone) on bulbourethral glands in the postnatal life of bucks and it can be concluded that testosterone helps in the development of the glandular parenchyma of bulbourethral glands that are essential for glandular secretion.

Table- 13: Capsular thickness of bulbourethral gland in goats (mean ± SE)

Parameter	Castrated goats Mean ± SE	Control goats Mean ± SE	Goats treated with exogenous testosterone, Mean ± SE
Capsular thickness of bulbourethral gland (μ); n=15	96.80 ± 9.93	76.00 ± 5.37	47.40 ± 7.47*

*p<0.05 (*t*-test)

SUMMARY AND CONCLUSIONS

Castration and exogenous administration of testosterone in goats affect significantly in certain blood constituents and lipid & protein profiles. Castration caused a significant decrease in RBC, PCV and percentage of lymphocytes accompanied with significantly increased MCV, MCH and percentage of neutrophils and the reverse result was observed in TE treated goats. The study showed a significant increase in the levels of TC, TG and LDL in castrated group compared with control value. Administration of TE exogenously significantly decreased the levels of TG and LDL compared with control group. A significant decline was observed in total protein, albumin and glucose level in castrated goats. Castration and administration of exogenous testosterone promoted changes in the biometric measures of the accessory sex glands. Analyzing weight, length and width of the vesicular glands and bulbo-urethral glands, a significant difference was observed between experimental groups comparing castrated, control and testosterone treated goats and the values were the lower in castrated and the higher in testosterone treated goats. The structures of male accessory sex glands were histologically similar in all three groups of goats, but differing in size. Histologically, the findings of the goats' accessory sex glands were almost similar to those of the cattle (according to the literature) except the corpus prostate (absent in goats). Increased level of testosterone decreased the tunica muscularis and adventitia in seminal vesicle and increased the size of glandular secretory units both of seminal vesicle and prostate glands. A negative relation was found between the level testosterone and the thickness of capsule of bulbo-urethral glands. The present study confirms the developmental and functional dependence of the male accessory reproductive glands on testosterone in the postnatal life of Black Bengal goats but the mechanism is still poorly understood.

REFERENCES

1. Adebayo AO, Oke BO and Akinloye AK (2009). The gross morphometry and histology of the male accessory sex glands in the greater cane rat (*Thryonomys swinderianus*). *J. Vet. Anat.* 2(2): 41 – 51.
2. Afolabi KD, Akinsoyinu AO, Olajide R and Akinleye SB (2010). Haematological parameters of the Nigerian local grower chickens fed varying dietary levels of palm kernel cake (p. 247). *Proceedings of 35th Annual Conference of Nigerian Society for Animal Production.*
3. Ahmed SA and Ahmed EA (2011). Behavioral responses of castrated buck kids at different ages by using different methods of castration. *J. Am. Sci.* 7: 200-209.
4. Aitken RN (1955). A histochemical study of the seminal vesicle of the sheep. *J. Anat., 89(4)*:430-9.
5. Alodan MA and Mashaly MM (1999). Effect of induced molting in laying hens on production and immune parameters. *Poultry Science.* 78(2): 171-177.
6. AL-Zghoul MBF, AL-Rukibat RK, Talafha AQ, Ababneh O and Ismail ZAB (2008). Cellular and some biochemical changes in blood and peritoneal fluid constituents in awassi lambs following elective castration. *American Journal of Animal and Veterinary Sciences.* 3 (1): 23-27.
7. Anderson RA, Wallace EM and Wu FC (1995). Effect of testosterone enanthate on serum lipoproteins in man. *Contraception.* 52(2):115-9.
8. Archana P, Katiyar RS, Sharma DN and Farooqui MM (2009). Gerentological studies on the gross and histomorphology of the vesicular gland of gaddi goat *(Copra hircus). Int. J. Morphol.,* 27(1):13-20.
9. Arthur GH (1975). Veterinary Reproduction and Obstetrics. 4th edn. Baillier Tindal, London. pp: 521-523.
10. Ashdown RR and Hafez ESE (1995). *Anatomia da Reprodução Masculina:* Reprodução animal. 6th. edn. São Paulo: Manole. cap. 1, p. 3-20.
11. Athure GH, Noakes DE and Pearson H (1996). Veterinary Reproduction and Obstetrics. W.B. Saunders Company Ltd. London. pp: 563-564.
12. Aydilek N and Aksakal M (2005). Effects of testosterone on lipid peroxidation, lipid profiles and some coagulation parameters in rabbits. *J Vet Med, A Physiol Pathol Clin Med.* 52(9): 436-9.
13. Babeker EA and Elmansoury YHA (2013). Observations concerning haematological profile and certain biochemical in Sudanese desert goat. *Online Journal of Animal and Feed Research.* 3(1): 80-86.

14. Bacha WJ and Wood LM (1990). Color Atlas of Veterinary Histology. Lea & Febiger. Philadelphia, London. pp.189-202.
15. Bai LS and Kurup PA (1976). Testosterone and lipid metabolism in rabbits. *Indian J Exp Biol.*14:705-7.
16. Baker JR (1927). The influence of age at castration on the size of various organs. *Brit. Jour. Exp. Biol.* 5:187.
17. BBS (Bangladesh Bureau of Statistics) (2012) (www.bbs.gov.bd) (Access date: Nov, 2013).
18. Barbara J, Sheri A, Hild A and Reel JR (2006). A new potent orally active androgen with progestational activity. *Endocrinology.* 147: (6) 3016-3026.
19. Bearden HJ and Funguay JW (2000). Applied Animal Reproduction. 5th edn. Printes and Hall. New Jersey, USA. pp: 30-33.
20. Berg G, Schreier L, Geloso G, Otero P, Nagelberg A and Levalle O (2002). Impact on lipoprotein profile after long-term testosterone replacement in hypogonadal men. *Horm Metab Res.* 34(2):87-92.
21. Berge OA (1958). Eefect of stilboestrol on the prostatic gland in normal puppies and adult dogs. *Acta Endocrinol*. 27(2): 155-69.
22. Bhasin S, Cunningham GR, Hayes FJ, *et al.* (2010). Testosterone therapy in men with androgen deficiency syndromes: an Endocrine Society clinical practice guideline. *J Clin Endocrinol Metab*. 95: 2536–2559.
23. Blandau RJ (1945). Factors involved in sperm transport through the cervix uteri of the albino rat. *Am. J. Anat.* 77: 253-272.
24. Bone JF (1988). Animal Anatomy and Physiology. 3rd edn. Prentice and Hall company, USA. pp: 406-409.
25. Bonneau M (2010). Accessory sex glands as a tool to measure the efficacy of immunocastration in male pigs. *Animal.* 4 (6): 930–932.
26. Brand JS, Schouw YT, Dowsett M, Folkerd E, Luben RN, Wareham NJ and Khaw KT (2012). Testosterone, SHBG and differential white blood cell count in middle-aged and older men. *Maturitas.* 71(3): 274-8. doi: 10.1016/j.maturitas.2011.12.007.
27. Brandes D (1974). Male Accessory Sex Organs: Structure and Function in Mammals. Academic, New York.
28. Bratzler LJ, Soule RP, Jr. Reineke EP and Paul P (1954). The effect of testosterone and castration on the growth and carcass characteristics of swine. *J. Anim. Sci*. 13:171-176.
29. Breazile JE, Beames CG, Cardielhag PT and Newcomer WS (1971). Textbook of Veterinary Physiology. Lea & Febiger, Philadelphia, USA. p-214.

30. Briggs MR, Yokoyama C, Wang X, Brown MS and Goldstein JL (1996). Nuclear protein that binds sterol regulatory element of low density lipoprotein receptor promoter. I. Identification of the protein and delination of its target nucleotide sequence. *J. Biol. Chem.* 268:14490-14496.
31. Calof OM, Singh AB, Lee ML, *et al.* (2005). Adverse events associated with testosterone replacement in middle-aged and older men: a meta-analysis of randomized, placebo-controlled trials. *J Gerontol A Biol Sci Med Sci*. 60:1451–1457.
32. Campos ACN (2003). *Morfometria do trato genital masculino*: influência do plasma seminal obtido em época seca ou chuvosa sobre espermatozóides caprinos. Fortaleza: Faculdade de Veterinária, Universidade estadual do Ceará. p. 82 [Tese de Doutorado em Ciências Veterinárias].
33. Carlson GP (1996). Clinical chemistry tests. In B. P. Smith (Ed.), Large Animal Internal Medicine. 2nd edn. Mosby Publisher. USA.
34. Cavazos LF (1975). Fine structure and functional correlates of male accessory sex glands of rodents. In Handbook of Physiology: Vol. 5. *Endocrinology*, pp. 353-381.
35. Chandrapal (1976). Gross histological and histochemical studies on the male genital system of buffalo (Bubalus bubalis). Ph.D. Thesis. Agra University, Agra.
36. Chinoy NJ, Sheth KM and Shah VC (1974). Effect of castration, testosterone treatment and vasoligation on nucleic acid and protein levels in accessory glands of guinea pigs. *Indian Journal of Medical Research*. 62(10):1529-1533.
37. Coles EH (1986). Veterinary Clinical Pathology. 2nd edn. W. B. Saunders company, Philadelphia, USA. Pp-13, 44-45, 126-127, 138-139.
38. Cons DN (1957). Some observations on the histology and histochemistry of the seminal vesicles of bulls. *J. Endocrinol., 14*:304-8.
39. Daramola JO, Adeloye AA, Fatoba TA and Soladoye AO (2005). Haematological and biochemical parameters of West African Dwarf goats. *Livestock Research for Rural Development.* 17(8): 95. Retrieved January 22, 2014, from www. lrrd.org/ lrrd17/8/dara17095.htm.
40. Davis LE, Widness JA and Brace RA (2003). Renal and placental secretion of erythropoietin during anemia or hypoxia in the ovine fetus. *Am. J. Obst. Gynecol.,* 189: 1764–1770.
41. Dellman HD and Wrobel KH (1976). Male reproductive system. In:Text book of Veterinary Histology. Dellman, H. D. & Brown, E. H. (Eds.). Philadelphia, Lea & Febiger. pp. 306-11.
42. Dellmann HD and Eurell JA (1998). A Textbook of Veterinary Histology. 5th edn., Williams and Wilkins, A Waverly Company, Philadelphia, USA. pp. 238-243.

43. Desjardin C and Jones RA (1970). Differential sensitivity of rat accessory sex tissues to androgen following neonatal castration or androgen treatment. *Anatomical Record.* 166: 299.
44. Desjardins C (1978). Endocrine regulation of the reproductive development and function in the male. *J. Anim. Sci.* 47: 56-79.
45. Dyce KM Sack WO and Wensing CJG (2002). Text book of Veterinary Anatomy. 3rd edn. W.B. Saunders Company, USA. pp: 188-190, 715-717.
46. Dyce KM, Sack WO and Wensing CLG (1987). Tratado De Anatomia Veterinaaria. 2nd edn. Rio De Janeiroi Guannabara Koogan. pp: 184-198.
47. Eliasson R and Lindholmer C (1976). Functions of male accessory genital organs. In Human Semen and Fertility Regulation in Man, pp. 44-50. Eds E.S.E. Hafez. Mosby Co., St. Louis.
48. Elitok B (2012). Reference values for hematological and biochemical parameters in saanen goats breeding in Afyonkarahisar province. *Kocatepe Vet J.* 5 (1): 7–11.
49. English HF, Santen RJ and Isaacs JT (1987). Response of glandular versus basal rat ventral prostatic epithelial cells to androgen withdrawal and replacement. *Prostate.* 11: 229-242.
50. Etim NN, Williams ME, Akpabio U and Offiong EEA (2014). Haematological parameters and factors affecting their values. *Agricultural Science.* 2(1): 37-47.
51. Evans HE and DeLahunta A (2004). Guide to the Dissection of the Dog. 6th edn. Elsevier and Saunders. New York. pp: 191-192.
52. Feldman *BV, Zinkl JG* and Jain NC (2000). Schalm's Veterinary Hematology. 5th edn. Lippincott Williiams & Wilkins, Philadelphia, USA. p-1077.
53. Fisher AD, Crowe MA, Alonso ME, Varga DL and Enright WJ (1996). Effect of castration method and the provision of local anaesthesia on plasma cortisol, scrotal circumference, growth and feed intake of bull calves. *J. Anim. Sci.* 74: 2336-2343.
54. Fisher AD, Crowe MA, O'nuallain EM, Monaghan ML, Prendiville DJ, O'kiely P and Enright WJ (1997). Effects of suppressing cortisol following castration of bull calves on adrenocorticotropic hormone, *in vitro* interferon-production, leukocytes, acutephaseproteins, growth, and feed intake. *J. Anim. Sci.* 75: 1899-1908.
55. Fisher AD, Knight TW and Cosgrove GP (2001). Effects of surgical or banding castration on stress responses and behavior of bulls. *Aust. Vet. J.* 79: 279-284.
56. Frandson, RD and Spurgeon TL (1992). Anatomy and Physiology of the Farm Animals. 5th edn., Lippincott Williams and Wilkins, A Wolters Company. Philadelphia, Baltimore, U.S.A. pp. 352-420.

57. Fried W and Gurney CW (1968). The erythropoietic-stimulating effects of androgens. *Ann N Y Acad Sci.* 149:356-65. http://dx.doi.org/10.1111/j.1749-6632.1968.tb15169.x
58. Ganz T and Nemeth E (2011). Hepcidin and disorders of iron metabolism. *Annu Rev Med*. 62: 347–360.
59. Getty R (1975). The Sisson and Grossman's the Anatomy of the Domestic Animals. Volume 1. 5th edn. W. B. Saunders Company. Philadelphia, London, Toronto. pp. 942 - 946.
60. Ghosh RK (1995). Primary Veterinary Anatomy. 1st edn. Current Books International. Calcutta. pp. 169.
61. Goldberg RB, Rabin D, Alexander AN, Doelle GC and Getz GS (1985). Suppression of plasma testosterone leads to an increase in serum total and high density lipoprotein cholesterol and apoproteins A-I and B. *J Clin Endocrinol Metab.* 60(1): 203-7.
62. Gonzalez FHD (2002). *Introdução à endocrinologia reprodutiva veterinária*. Porto Alegre: Laboratório de Bioquímica Clínica Animal.
63. Gridley MF (1960). Manual of Histologic and Special Staining Technique. 2nd edn. McGraw-Hill Book Company. USA. pp. 28-31.
64. Gupta AN (1978). Histological and histochemical studies on the accessory genital glands of normal and castrated bucks. M.V.Sc. thesis. Haryana Agricultural University, Hisar, India.
65. Gupta AN (1989). Correlative Anatomy of the testes, epididymis and accessory sex glands in goat. Ph.D Thesis, HAU, Hisar, India.
66. Gupta AN and Singh Y (1982). Histological and histochemical studies on the prostate gland of goat. *Indian J. Anim. Sci., 52*:82-9.
67. Gupta V, Bhasin S, Guo W, Singh R, Miki R, Chauhan P, Choong K, Tchkonia T, Lebrasseur NK, Flanagan JN, Hamilton JA, Viereck JC, Narula NS, Kirkland JL and Jasuja R (2008). Effects of dihydrotestosterone on differentiation and proliferation of human mesenchymal stem cells and preadipocytes. *Mol Cell Endocrinol.* 296:32-40.
68. Hafez ESE (1974). Reproduction in Farm Animals. 3rd edn. Philadelphia, Lea and Febiger. pp: 31-32.
69. Hafez ESE (1976). Human Semen and Fertility Regulation in Men. Mosby Co., St. Louis. pp. 44-50.
70. Hafez ESE (1987). Reproduction in Farm Animals. 5th edn. Philadelphia, Lea and Febiger. pp. 26-27.
71. Harvey DG (1962). Biochemistry for Veterinary Students. 1st edn. Blackwell scientific publications, Oxford. pp- 134-135.

72. Hassan AA (2010). Effect of castration on some physiological aspect in rats: Effect of testosterone hormone. *J. Edu. & Sci.,* 23(3): 28-39.
73. Hemeida NA (1985). The reproductive tract of the Caprine Egyption balady bucks. *Assiut Vet Med J.* 14(28): 204-210.
74. Herring MJ, Oskui PM, Hale SL and Kloner RA (2013). Testosterone and the Cardiovascular System: A Comprehensive Review of the Basic Science Literature. *J Am Heart Assoc.* 2: e000271; doi: 10.1161/JAHA.113.000271.
75. Hib J (2003). *Di fiore histologia*: texto e atlas. Rio de Janeiro: Guanabara Koogan. p. 530.
76. http://www.britannica.com (Animal-reproductive-system, Encyclopedia Britannica, by George C. Kent, Jr.; Alumni Professor Emeritus of Zoology, Louisiana State University, Baton Rouge and Author of Comparative Anatomy of the Vertebrates) (Access date: Nov, 2013)
77. Hussein SA, Azab ME and Abdel-Maksoud H (1999). Metabolic changes concerning the effect of castration on some blood constituents in male rabbits. *Dtsch Tierarztl Wochenschr.* 106(3):113-8.
78. Huttunen ET, Romppanen T and Helminen HJ (1981). A histoquantitative study on the effects of castration on the rat ventral prostate lobe. *J. Anat.* 132: 357-370.
79. Isaac LJ, Abah G, Akpan B and Ekaette IU (2013*).* Haematological properties of different breeds and sexes of rabbits (pp. 24-27). *Proceedings of the 18th Annual Conference of Animal Science Association of Nigeria.*
80. Jean-Faucher C, Berger M, Gallon C, DeTurckheim M, Veyssiere G and Jean C (1986). Imprinting of male sex tissues by neonatal endogenous androgens in mice. *Hormone Research.* 24: 38–45.
81. Jiang HY, Lee KH, Tang PL and Chow PH (2001). Ablation of paternal accessory sex glands is detrimental to embryo development during implantation*. Anat Embryol (Berl).* 203(4): 255-63.
82. Jockenhövel F, Bullmann C, Schubert M, Vogel E, Reinhardt W, Reinwein D, Müller-Wieland D and Krone W (1999). Influence of various modes of androgen substitution on serum lipids and lipoproteins in hypogonadal men. *Metabolism.* 48(5): 590-6.
83. Johnston JK and Morris DD (1996). Alterations in blood proteins. In B. P. Smith (Ed.), International Animal Medicine*.* 2nd edn. Mosby Publishers. USA.
84. Junqueira LC and Carneiro J (2008). *Histologia básica*: texto e atlas. 11th edn. Rio de Janeiro: Guanabara Koogan. p. 524.

85. Kelani OL and Durotoye LA (2002). Haematological responses of the African giant rat (Cricetomis gambianus) to castration and androgen replacement. *Vetreinarski Arhiv.,* 72(1): 39-49.
86. Khalaf AS and Merhish SM (2010). Anatomical study of the accessory genital glands in male sheep (*Ovis aris*) and goats (*Caprus hircus). Iraqi J. Vet. Med.* 34 (2): 1 – 8.
87. Khan MZ, Szarek, J, Koncicki A and Krasnodebska-Depta A (1994). Oral administration of monensin and lead to broiler chicks: effect on haematological and biochemical parameters. *Acta Veterinaria Hungarica,* 42(1): 111-120.
88. Khan TA and Zafar F (2005). Haematological study in response to varying doses of estrogen in broiler chicken. *International Journal of Poultry Science,* 4(10): 748-751.
89. Kumar VL and Majumdar PK (1995). Prostate gland: Structure, functions and regulation. *International urology and nephrology*. 27 (3): 231-243.
90. Kundu PB (1980). Anatomical studies on the accessory male sex glands (gross and microscopic) of the Indian goat (Jamunapari and cross Jamunapari). *Indian J. Anim. Health, 19*:151-3.
91. Land RB and Robinson DW (1985). Genetics of Reproduction in Sheep. Butter Worths company. London. pp: 81-84.
92. Leblanc M, Bélanger M, Julien P, Tchernof A, Labrie C, Bélanger M and Labrie F (2004). Plasma lipoprotein profile in the male cynomolgus monkey under normal hypogonadal and combined androgen blockade conditions. *J. Clin. Endocrinol. Metab.,* 89 (4): 1849-1857.
93. Malgor LA, Valsecia M, Verges E, *et al.* (1998). Blockade of the in vitro effects of testosterone and erythropoietin on Cfu-E and Bfu-E proliferation by pretreatment of the donor rats with cyproterone and flutamide. *Acta Physiol Pharmacol Ther Latinoam.* 48:99-105.
94. Martins JAM (2006). Avaliação da biometria testicular, epididimal e das glândulas sexuais acessórias e correlações entre características biométricas e histológicas em carneiros deslanados sem padrão racial definido (SPRD). Fortaleza: Faculdade de Veterinária, Universidade Federal do Ceará. P: 51 [Dissertação de Mestrado em Zootecnia].
95. McDonald LE (1980). Veterinary Endocrinology and Reproduction. 3rd edn. Lea and Febiger. pp: 249-250.
96. Merck Manual (2012). Haematologic reference ranges. *Mareck Veterinary Manual.* Retrieved at April 20, 2014 from http://www.merckmanuals.com.

97. Meriggiola MC, Marcovina S, Paulsen CA and Bremner WJ (1995). Testosterone enanthate at a dose of 200 mg/week decreases HDL-cholesterol levels in healthy men. *Int J Androl.* 18(5): 237-42.
98. Mifune H, Noda Y, Mohri S, Suzuki S, Nishinakagawa H and Otsuka J (1986). Fine structure of the seminal vesicle epithelium of the mouse and golden hamster. *Jikken Dobutsu.* 35(2):149-58.
99. Mirand EA, Gordon AS and Wenig J (1965). Mechanism of testosterone action in erythropoiesis. *Nature*. 206 (981): 270–272.
100. Mmereole FUC (2008). The effects of replacing groundnut cake with rubber seed meal on the haematological and serological indices of broilers. *International Journal of Poultry Science,* 7(6): 622-624.
101. Mollineau WM, Adogwa AO, Garcia GW (2009). The gross and micro anatomy of the accessory sex glands of the male agouti (*Dasyprocta leporina*). *Anat Histol Embryol.* 38(3): 204-7
102. Molony V, Kent JE and Robertson IS (1995). Assessment of acute and chronic pain after different methods of castration of calves. *Appl. Anim. Behav. Sci*. 46: 33-48.
103. Monfared AL (2013). Correlation of serum lipid profile with histological and seminal parameters of testis in the goat. *Int J Fertil Steril*. 7(2): 122-129.
104. Moorjani S, Dupont A, Labrie F, Lupien PJ, Gagné C, Brun D, Giguère M, Bélanger A and Cusan L (1988). Changes in plasma lipoproteins during various androgen suppression therapies in men with prostatic carcinoma: effects of orchiectomy, estrogen, and combination treatment with luteinizing hormone-releasing hormone agonist and flutamide. *J Clin Endocrinol Metab.* 66(2): 314-22.
105. Neves CC, Artoni SMB, Pacheco MR, Feliciano MAR, Amoroso L and Melo DG (2013). Morphology and biometric of the vesicular and bulbourethral glands in castrated and non-castrated Santa Ines breed sheep. *J. Morphol. Sci.* 30 (2): 115-120
106. Nickel R, Schummer A and Seiferley E (1973). The Viscera of the Domestic Mammals. 1st edn. Verlag paul Parey. New York. pp: 291-336.
107. Nielsen EH (1976). The bulbourethral gland of the rat. Fine structure and histochemistry. *Anat Anz.* 139(3): 254-63.
108. Nunes JF (1982). Étude des effets du plasma seminal sur la survie in vitro dês espermatozóides de bunc. Paris: Université Paris. p. 45 [Tese de Doutorado Ciência da Vida].
109. Oduye OO (1976). Haematological values of Nigerian goats and sheep. *Trop. Animal Health and prod.* 8:131-136.

110. Ogunbajo SO, Alemede IC, Adama JY and Abdullahi J (2009). Haematological parameters of Savannah brown does fed varying dietary levels of flamboyant tree seed meal (p. 88-91). *Proceedings of 34th Annual Conference of Nigerian Society for Animal roduction.*

111. Olafedehan CO, Obun AM, Yusuf MK, Adewumi OO, Oladefedehan AO, Awofolaji AO and Adeniji AA (2010). Effects of residual cyanide in processed cassava peal meals on haematological and biochemical indices of growing rabbits (p.212). *Proceedings of 35th Annual Conference of Nigerian Society for Animal Production.*

112. Olaifa AK and Opara MN (2011). Haematological and biochemical parameters of West African Dwarf (WAD) bucks castrated by the Burdizzo method. *Vet. Arhiv.* 81: 743-750.

113. Olamide AA, Kayode AO, Nervey WD, Lukeman A.JS, Olusoji AO and Abayomi OO (2007). Sex steroid induced changes on the morphology of prostate of sprague-dawley rats. *Scientific Research and Essay.* Vol. 2 (8): 309-314.

114. Oppenheim DS, Greenspan SL, Zervas NT, *et al*. (1989). Elevated serum lipids in hypogonadal men with and without hyperprolactinaemia. *Ann. Intern. Med.* 111: 288–92.

115. Otesile EB, Fagbemi BO and Adeyemo O (1991). The effect of Trypanosoma brucei infection on serum biochemical parameters in boars on different planes of dietary energy. *Vet. Parasitol.,* 40(3-4): 207-216.

116. Ovuru SS and Ekweozor IKE (2004). Haematological changes associated with crude oil ingestion in experimental rabbits. *African Journal of Biotechnology,* 3(6): 346-348.

117. Oyeyemi MO, Bamidele TO, Jolaoso VBO and Akingbogun OK (2001). The effect of feed supplementation on the weight changes, liver enzymes and some minerals in adult WAD does. *Nig. Vet. J.,* 22(1): 43-52.

118. Oyeyemi MO, Oliafa AK, Onwuka SK, Akinloye AK and Utho OA (2000). The effects of bilateral orchidectomy on some serum enzymes and proteins in the West African dwarf buck. *Afr. J. Biomed. Res.* 3: 105 – 108.

119. Pang SF, Chow PH and Wong TM (1979). The role of the seminal vesicles, coagulating glands and prostate glands on the fertility and fecundity of mice. *J. Reprod. Fert.* 56: 129-132.

120. Pathak A, Katiyar RS, Sharma DN, Farooqui MM and Prakash A (2012). Gross anatomical, histological and histochemical studies on the postnatal development of the prostate gland of Gaddi goat. *Int. J. Morphol.,* 30(2):731-739.

121. Pineda M and Dooley MP (2003). McDonald's Veterinary Endocrinology and Reproduction. 5th edn. Blackwell Publishing Ltd. UK. pp-258-261.

122. Plumb DC (1999). Veterinary Drug Handbook. Iowa State University Press, USA. Retrieved April 20, 2014, from http://goat-link.com.
123. Raeside JI, Friendship RM and Vrablic OE (1997). Effects of castration on early postnatal development of male accessory sex glands in the domestic pig. *Eur J Endocrinol.,* 137(3): 287-92.
124. Reece OR (1991). Physiology of Domestic Animals. 12th edn. Lea & Febiger, Philadelphia, USA. p-103.
125. Risbridger GP and Taylor RA (2006). Physiology of male acessory sex structures: the prostate gland, seminal vesicles, and bulbourethral glands. *Knobil and Nell`s Physiology of Reproduction.* 23: 1149-1172.
126. Roubies N, Panousis N, Fytianou A, Katsoulos PD, Giadinis N and Karatzias H (2006). Effects of age and reproductive stage on certain serum biochemical parameters of Chios sheep under Greek rearing conditions. *J. Vet. Med. A Physiol. Pathol. Clin. Med.,* 53: 277-281.
127. Roy KS, Pawar HS and Saigal RP (1985). Histomorphological, histochemical and histoenzymological studies on prostate gland of ram (*Ovis aries*). *Indian J. Anim. Sci., 55(12)*: 983-6.
128. Rudolph GG and Starnes WR (1954). Effect of castration and testosterone administration on seminal vesicle and prostates of rats. *American Journal of Physiology.* 179 (3): 415-418.
129. Sastry GA (1983). Veterinary Clonical Pathology. 3rd edn. CBS publishers & distributors, New Delhi, India. pp- 14-41.
130. Seiser PE, Duffy LK, David MA, Roby DD, Golet GH and Litzow MA (2000). Comparison of pigeon guillemot, Cepphus columba, blood parameters from oiled and unoiled areas of Alaska eight years after the Exxon Valdez oil spill. *Marine Pollution Bulletin,* 40(2): 152-164.
131. Shahani S, Braga-Basaria M, Maggio M and Basaria S (2009). Androgens and erythropoiesis: past and present. *J Endocrinol Invest*. 32 (8): 704–716.
132. Shively MJ (1982). Veterinary Anatomy (Basic, comparative and clinical). Texas A and M. University press college station. USA. pp: 349-351.
133. Sisson S (1975). Sisson & Grossman's The Anatomy of the DomesticAnimals. Getty, R. (Ed.). 5th edn. Vol. 1. Philadelphia, W. B. Saunders Co. pp. 768-9.
134. Slater CH and Schreck CB (1997). Physiological levels of testosterone kill salmonid leukocytes in vitro. *General and Comparative Endocrinology*, 106: 113 – 119.
135. Smith BJ (1999). Canine Anatomy. Lippincott Williams and Wilkins. USA. pp: 445-478.

136. Sohmiya M and Kato Y (2005). Human growth hormone and insulin-like growth factor-I inhibit erythropoietin secretion from the kidneys of adult rats. *J. Endocrinol.,* 184: 199-207.
137. Solaiman SG, Shoemaker CE, Jones WR and Kerth CR (2006). The effects of high levels of supplemental copper on the serum lipid profile, carcass traits, and carcass composition of goat kids. *J. Anim. Sci*. 84(1): 171-177.
138. Sourla A, Martel C, Labrie C and Labrie F (1998). Almost exclusive androgenic action of dehydroepiandrosterne in rat mammary gland. *Endocrinology.* 139:753-764.
139. Stafford KJ (2007). Alleviating the pain caused by the castration of cattle. *Vet. J.,* 173: 333-342.
140. Sudhakar LS (1982). Histological and histochemical changes in the male accessory genital glands of Murrah buffalo during postnatal development. Ph.D. Thesis. Haryana Agricultural University, Hisar, India.
141. Sudhakar LS, Dhingra LD and Sharma DN (1986). Postnatal histomorphology of the vesicular gland in *Murrah buffalo* bull. *Indian J. Anim. Sci., 56*: 866-9.
142. Sultana M, Verma PK, Raina R, Pankaj NK, Dubey N, Khan AM and Naseem S (2011). Evaluation of biochemical indices in pregnant and non-pregnant goats. *Journal of Research, SKUAST-J,* 10(1): 113-116.
143. Svoboda M, Eichlerova K, Horak V and Hradecky J (2005). Development of haematological indices in melanoma-bearing liběchov minipigs. *Acta Veterinaria Brno,* 74(4): 603-611.
144. Swenson MJ (1977). Duck's Physiology of Domestic Animals. 9th edn. CBS publishers & distributors, New Delhi, India. pp- 14-35.
145. Tartakovsky B, De Baetselier P, Feldman M and Segal S (1981). Sex associated differences in the immune response against fetal major histocompatibility antigens. *Transplantation*. 32:395.
146. Tchernof A, Labrie F, Belanger A, Prud JP, Bouchard C, Tremblay A, Nadeau A and Despre JP (1997). Relationships between endogenous steroid hormone globulin and lipoprotein levels in men: contribution of visceral obesity, insulin levels and other metabolic variables. *Atherosclerosis,* 133 (2): 235-244.
147. Tenover JS (1992). Effects of testosterone supplementation in the aging male. *J Clin Endocrinol Metab.* 75(4):1092-8.
148. Thomas ME, Michael TM, Phong TL, Robert CF and Eugene DK (2001). Alteration in peripheral B cells and B cell progenitors following androgen ablation in mice. *Int. J. Immunol.,* 13(13): 553-558.

149. Tikkanen MJ and Nikkila EA (1987). Regulation of hepatic lipase and serum lipoproteins by sex steroids. *Am. Heart J.* 113:562-7. http://dx.doi.org/10.1016/0002-8703(87)90633-8.

150. Togun VA, Oseni BSA, Ogundipe JA, Arewa TR, Hammed AA, Ajonijebu DC, *et al.* (2007). Effects of chronic lead administration on the haematological parameters of rabbits – a preliminary study (p. 341). *Proceedings of the 41st Conferences of the Agricultural Society of Nigeria.*

151. Tras B, Inal F, Bas AL, Altunok V, Elmas M and Yazar E (2000). Effects of continuous supplementations of ascorbic acid, aspirin, vitamin E and selenium on some haematological parameters and serum superoxide dismutase level in broiler chickens. *British Poultry Science,* 41(5): 664-666.

152. Trautmann A and Fiebiger J (1957). Fundamentals of Histology of Domestic Animals. Translated and revised by Habel, R. E. & Bibertein, S. L. Comstock Publishing Associates. Ithaca. pp: 269-72.

153. Tyagi A, Rajalakshmi M, Jeyaraj DA, Sharma RS and Bajaj JS (1999). Effects of long-term use of testosterone enanthate. II. Effects on lipids, high and low density lipoprotein cholesterol and liver function parameters. *Int J Androl.* 22(6): 347-55.

154. Uyanik BS, Ari Z, Gümüs B, Yiğitoğlu MR and Arslan T (1997). Beneficial effects of testosterone undecanoate on the lipoprotein profiles in healthy elderly men. A placebo controlled study. *Jpn Heart J*. 38(1):73-82.

155. Vecerek V, Strakova E, Suchy P and Voslarova E (2002). Influence of high environmental temperature on production and haematological and biochemical indexes in broiler chickens. *Czech Journal of Animal Science.* 47(5): 176-182.

156. Vizzotto L, Dolci C, Pandolfi M, Pizzichini M and Marinello E (1995). Morphometric evaluation of rat liver after castration: effect of testosterone. *Int J Tissue React*. 17 (2): 73-79.

157. Wang X, Briggs MR, Hua X, Yokoyama C, Goldstein JL and Brown MS (1993). Nuclear protein that binds sterol regulatory element of low density lipoprotein receptor promoter. II. Purification and characterization. *J. Biol. Chem.,* 268:14497-14504.

158. Wennstrom KL and Crews D (1998). Effect of long-term castration and long-term androgen treatment on sexually dimorphic estrogen inducible progesterone receptor Mrna levels in the vento-medial hypothalamus of whiptail lizards. *Hormone and Behavior.,* 34:11-16.

159. Windmill KF and Lee VW (1998). Effects of castration on the lymphocytes of the thymus, spleen and lymph nodes. *Tissue Cell.* 30(1):104-11.

160. Winters SJ (1999). Current status of testosterone replacement therapy in men. *Arch Fam Med.* 8:257-63. http://dx.doi.org/10.1001/archfami.8.3.257.
161. www.campus.murraystate.edu/academic/faculty/tderting/Research_Website/TestosteroneExpt/Testosteron_02Research.html. The effects of testosterone on immunocompetence: Immunosuppression or Immunoredistribution? (Access date: 20 Feb, 2014)
162. Xie L, Xu F, Liu S, Ji Y, Zhou Q, Wu Q, *et al.* (2013). Age- and sex-based hematological and biochemical parameters for *Macaca fascicularis*. *PLoS ONE, 8*(6): e64892. doi:10.1371/journal.pone.0064892.
163. Xu T, Wang X, Hou S, Zhu J, Zhang X and Huang X (2003). Effect of surgical castration on risk factor for arteriosclerosis of patients with prostate cancer. *Clin. Med. J.,* 15:1336-1340.
164. Yao TS and Eaton ON (1954). Postnatal growth and histological development of reproductive organs in male goats. *Am. J. Anat., 95(3)*:401-31.
165. Youngquist and Threlfall WR (2007). Current Therapy in Large Animal Theriogenology, 2nd edn. Saunders. USA. pp. 511-513.
166. Zhao C, Moon DG and Park JK (2013). Effect of testosterone undecanoate on hematological profiles, blood lipid and viscosity and plasma testosterone level in castrated rabbits. Cited as: *Can Urol Assoc J.* 7(3-4): E221-5. doi: 10.5489/cuaj.507.
167. Zmuda JM, Fahrenbach MC, Younkin BT, Bausserman LL, Terry RB, Catlin DH and Thompson PD (1993). The effect of testosterone aromatization on high-density lipoprotein cholesterol level and postheparin lipolytic activity. *Metabolism*, 42: 446–450.